

## Clinical outcome by using mayo elbow performance score after elbow reconstruction with two plates in inverted y configuration for distal humerus intercondylar fractures

Muhammad Inam, Obaidullah Khan, Muhammad Saeed, Zeeshan Faisal, Nida Shahid

### Abstract:

**Objective:** The objective of this study was to assess the clinical outcome using the Mayo Elbow Performance Score after reconstructing the elbow with the application of two plates in an inverted Y configuration for distal humeral intercondylar fractures.

**Material and Methods:** This descriptive case series study was carried out at the Department of Orthopedics, Maqsood Medical Center, Peshawar, from June 2018 to June 2022. Non-probability, consecutive sampling technique was used for patient's selection. All patients with distal humeral intercondylar fracture aged between 20-50 years, either gender with a duration of fracture <1 week were included in the study. All the data were put in the SPSS version 20 and was analyzed for mean, mode, median and frequencies.

**Results:** Out of the 88 patients, 53(60.23%) were male and 35(39.22%) were females with male to female ratio of 1.5:1. Mean duration of fracture was  $4.19 \pm 1.44$  days. Mean BMI was  $29.0 \pm 3.12$  kg/m<sup>2</sup>. In current study, according to mayo elbow performance score clinical outcome was excellent in 27(30.68%), good in 37(42.05%), fair in 16(18.18%) and poor in 08(9.09%) patients after elbow reconstruction using two plates in inverted Y configuration for distal humeral intercondylar fracture.

**Conclusion:** The findings of this study indicate that a significant proportion of patients achieved a satisfactory clinical outcome when assessed with the Mayo Elbow Performance Score following elbow reconstruction using two plates arranged in an inverted Y configuration for distal humeral intercondylar fractures.

**Keywords:** Fracture, supracondylar, humerus, elbow, performance score

### Introduction:

Distal humerus fractures are relatively rare, accounting for only 0.5 to 2% of all fractures, but they are more common when it comes to elbow injuries, constituting up to 30% of all elbow fractures. In adults, these fractures typically occur within the joint and affect both the inner and outer columns of the humerus bone. The occurrence of distal humerus fractures tends to follow a pattern with two distinct peaks in terms of age distribution.<sup>1</sup> Younger patient are more likely to experience high-energy injuries, whereas older patients are prone to low-energy injuries.<sup>2</sup> A comprehensive grasp of the distal humerus anatomy is vital for successfully treating fractures in

this region. The distal humerus' articular surface is upheld by two separate bone columns, one situated on the inner (medial) and the other on the outer (lateral) side, forming a configuration reminiscent of an inverted -Y shape.<sup>3</sup>

Various classification systems exist for distal humerus fractures, and they are primarily based on factors like the participation of the medial and lateral columns of the humerus and the presence of specific fracture patterns in either the sagittal or coronal planes. For example, Riseborough and Radin's classification focuses on categorizing these fractures according to the condition of the condylar fragments.<sup>4</sup> Lecestre and

### Received

date: 20th January, 2023

### Accepted

date: 2nd July, 2023

Lady Reading Hospital,  
Peshawar  
M Inam

Maqsood Medical Center,  
Peshawar  
O Khan

Khyber Girls Medical  
College, MTI Hayatabad  
Medical Complex,  
Peshawar  
M Saeed

Hamdard University  
Hospital, Karachi  
Z Faisal  
N Shahid

### Correspondence:

Dr Obaidullah Khan  
Consultant Orthopedic  
Surgeon, Maqsood  
Medical Center, Ring Road  
Peshawar  
email: drminamkhan71@  
gmail.com

Table 1: Age distribution of patients (n=88)

Age (in years)	No. of patients	%age
20-35	36	40.91
36-50	52	59.09
Total	88	100.0

Mean ± SD = 37.41 ± 7.19 years

Table 2: Distribution of patients according to duration of fracture (n=88)

Duration (days)	No. of Patients	%age
0-3	29	32.95
4-6	59	67.05
Total	88	100.0

Mean±SD = 4.19±1.44 days

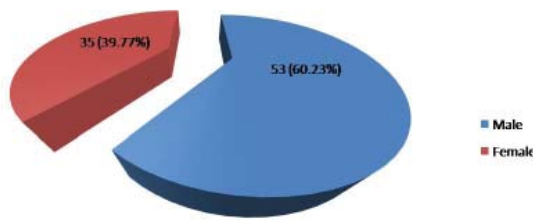


Figure-1: Distribution of patients according to gender (n=88)

Table 3: Distribution of patients according to BMI (n=88)

BMI (kg/m <sup>2</sup> )	No. of Patients	%age
≤27	30	34.09
>27	58	65.91
Total	88	100.0

Mean±SD = 29.03 ± 3.12 kg/m<sup>2</sup>

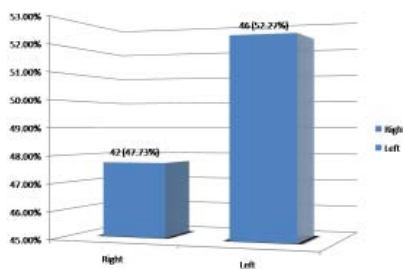


Figure-2: Distribution of patients according to side affected (n=89)

colleagues introduced a classification system that categorizes fractures of the distal humerus into four distinct types: supracondylar, extra-articular condylar, articular intercondylar, and comminuted fractures.<sup>5</sup> Jupiter developed his classification system by observing fractures during surgery, which resulted in categories such as high T, low T, Y, H, medial, and lateral lambda

fractures. On the other hand, the Dubberley classification system differentiates between fractures that affect either the capitellum or trochlea and provides specific treatment strategies for each type.<sup>6</sup> Internationally, the widely adopted classification system for fractures is the AO classification, which traditionally classifies fractures into three main categories: extra-articular, partial articular, and articular fractures.<sup>7</sup>

Surgical intervention is considered the preferred approach, with conservative treatment having a limited role in the management of distal humerus fractures.<sup>8</sup> Non-surgical treatment appears to be a viable option only when dealing with fractures that haven't shifted from their original position, for patients who are not deemed suitable for surgery, or as a temporary measure for elderly individuals before undergoing arthroplasty to prevent joint stiffness and abnormal bone growth.<sup>9</sup>

Utilizing two plates for open reduction with internal fixation to achieve bi-columnar stabilization has been a well-established and effective treatment approach, resulting in favorable clinical results.<sup>10</sup> There are various approaches to plate placement in practice. The commonly employed dual plating method encompasses perpendicular, parallel, and Y-shaped plating. In Y plating, two plates are positioned along the posterior surface of the medial and lateral supracondylar ridges in the coronal plane.<sup>11-13</sup> In a research study, the clinical outcomes were assessed using the Mayo Elbow Performance Score following elbow reconstruction with two plates arranged in an inverted Y configuration for distal humeral intercondylar fractures. The results showed that 20% of patients had excellent outcomes, 50% had good outcomes, 25% had fair outcomes, and 10% had poor outcomes.<sup>14</sup>

Several studies have explored and compared perpendicular and parallel plating techniques, but there is limited research on the outcomes of Y-shaped plating using two plates, and no local data is accessible on this subject. Therefore, the main goal of this study was to assess clinical

Table 4: Distribution of patients with respect to type of fracture (n=88)

Type of fracture	Frequency	%age
I	16	18.18
II	35	39.77
III	30	34.09
IV	07	7.95




Figure 3: Distribution of patients according to diabetes mellitus (n=88)

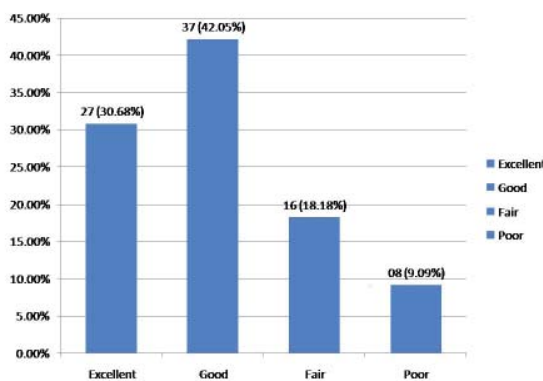


Figure 4: Clinical outcome by using Mayo Elbow Performance Score after elbow reconstruction using two plates in inverted Y configuration for distal humeral intercondylar fracture (n=89).

outcomes, as measured by the Mayo Elbow Performance Score, following elbow reconstruction with two plates arranged in an inverted Y configuration for distal humeral intercondylar fractures.

**Material and Methods:**

This Descriptive case series study was carried out at the Department of Orthopedics Maqsood Medical Center, Peshawar from June 2018 to June 2022. Non-probability, consecutive sampling technique was used for patient’s selection.

All patients with distal humeral intercondylar fracture aged between 20-50 years, either gender with a duration of fracture <1 week were included in the study. Patients with previous

surgical intervention to the same elbow, having congenital joint deformity, open fractures, patients with head injury and polytrauma, patients with any chronic disease i.e., chronic renal failure (serum creatinine >1.5 mg/dl), chronic liver disease (serum bilirubin >2.0 mg/dl) were excluded from the study.

Approval from the institutional ethical review committee was taken. The patients were entered in the study after taking informed written consent. In all patients, elbow reconstruction using two plates in inverted Y configuration through trans olecranon approach. All data (age, gender, duration of fracture, type of fracture, side affected, BMI, diabetes mellitus (DM) and clinical outcome) was recorded on a specially designed Performa. The collected information was analyzed by computer software SPSS version 20.0.

Mean and standard deviation were calculated for age, duration of fracture, BMI and Mayo Elbow Performance score. Frequency and percentage were calculated for qualitative variables i.e., gender, side affected (left/right), type of fracture (I/II/III/IV), diabetes mellitus (yes/no) and clinical outcome (excellent/good/fair/poor).

**Results:**

Age range in this study was from 20 to 50 years with mean age of 37.41±7.19 years. Majority of the patients 52(59.09%) were between 36 to 50 years of age as shown in table I.

Out of the 88 patients, 53(60.23%) were male and 35(39.22%) were females with male to female ratio of 1.5:1 shown in figure I. Mean duration of fracture was 4.19±1.44 days as shown in table II. Mean BMI was 29.03±3.12 kg/m<sup>2</sup> as shown in table III. Distribution of patients according to side affected, type of fracture and diabetes mellitus is shown in figure II, table IV and figure III respectively

In current study, according to Mayo Elbow Performance score clinical outcome was excellent in 27(30.68%), good in 37(42.05%), fair in 16(18.18%) and poor in 08(9.09%) patients

after elbow reconstruction using two plates in inverted Y configuration for distal humeral intercondylar fracture as shown in Figure VI. Stratification of satisfactory outcome with respect to age groups and gender is shown in table V and VI respectively.

#### **Discussion:**

In adults, fractures occurring in the distal humerus account for 2% of all fractures and represent around 30% of all humeral fractures.<sup>15</sup>

At a rate of 5.7 cases per 100,000 individuals annually, these fractures typically exhibit a bimodal distribution, with distinct patterns observed in young males resulting from high-energy trauma and in elderly females due to osteoporotic fractures.<sup>16</sup>

Therefore, given the aging population and the ongoing trend of increased motorization in developing regions, it is anticipated that the incidence of distal humerus fractures will rise similarly to the rates observed for fractures in the distal radius, hip, and spine.<sup>17</sup> Anatomically, the distal humerus has a triangular shape which is built of two columns and a “tie arch”.<sup>18</sup>

The distal part of the medial column contains the nonarticular medial epicondyle, which serves as the attachment point for flexor muscles, along with the medial portion of the humeral trochlea. On the other hand, the distal end of the lateral column encompasses the capitellum and, situated slightly higher, the lateral epicondyle, which serves as the attachment site for extensor muscles (known as the mobile wad). When viewed from the side, the articular surfaces of the trochlea and capitellum project forward at an angle of 40° in relation to the humerus' axis. Furthermore, the trochlear axis is externally rotated at an angle ranging from 3° to 8° compared to the longitudinal axis, which is positioned at 4° to 8° of valgus.<sup>18</sup> In correlation to the above-mentioned bimodal distribution of age,<sup>16</sup> mainly two fracture mechanisms can be distinguished: low-energy trauma, typically observed in elderly individuals, which can result from a

direct impact on the elbow or an indirect impact stemming from a fall onto an outstretched hand; and high-energy trauma, more commonly seen in younger patients, often caused by incidents such as road traffic accidents or sports-related injuries.<sup>17</sup>

Surgical intervention is considered the preferred and most effective approach, with conservative treatment playing a limited role in the management of distal humerus fractures.<sup>19</sup> Non-surgical treatment appears to be a suitable option only in situations involving fractures that have not shifted from their original position, for patients who are not deemed suitable candidates for surgery, or as a temporary measure for elderly individuals before undergoing arthroplasty to prevent joint stiffness and the development of abnormal bone growth.<sup>20</sup>

It is crucial to attain a stable internal fixation and restore the anatomy accurately to enable an early range of motion exercises, promote proper bone healing, and prevent potential cartilage degeneration in the future.<sup>21,22</sup>

Biomechanical research has shown that utilizing two plates instead of one offers clear benefits in terms of stability and rigidity, particularly in proximal and intra-articular fractures of the distal humerus.<sup>23</sup> The conventional fixation method employed by the majority of surgeons involves the use of two plates positioned at right angles to each other.<sup>22</sup>

However, studies conducted on cadavers as early as 1994 have reported that plates positioned in parallel or perpendicular orientations to each other offer similar levels of rigidity.<sup>24</sup>

Korner et al. conducted a comparison between the 90° offset method and plates positioned dorsally in artificial bone models, and they found that the group with plates placed perpendicularly achieved superior outcomes.<sup>21</sup> Further biomechanical studies, which distinguished between fracture patterns with or without bone loss, indicate that when there is a gap between the frag-

ments, the 180° plate arrangement exhibits the highest level of rigidity, followed by the perpendicular configuration and a dorsal arrangement. However, when there was no gap between the bone fragments, there were no significant differences in rigidity observed among the three fixation configurations.<sup>25</sup>

In clinical studies conducted by Shin and colleagues, it was observed that there was a higher incidence of non-union in the perpendicular plating group. However, there were no notable differences in terms of clinical outcomes when compared to the parallel plating group.<sup>26</sup> whereas Lee et al. highlighted no statistically significant differences concerning the clinical outcome and union time between the two groups.<sup>22</sup>

It remains unclear to what degree particular fracture patterns of the distal humerus can be associated with a specific plating technique. Perpendicular plating could be beneficial for coronal shear fractures, offering increased stability in the coronal plane. On the other hand, parallel plating might be the preferred choice for fractures in the very distal part of the humerus, as it allows for the option of additional screw fixation in that region.<sup>22</sup>

In a study, according to Mayo Elbow Performance Score clinical outcome was excellent in 20% good in 50% fair in 25% and poor in 10% patients after elbow reconstruction using two plates in inverted Y configuration for distal humeral intercondylar fracture which is comparable to current study.<sup>14</sup>

In another study,<sup>27</sup> a total number of 60 patients with Riseborough and Radin type II, III, and IV intercondylar humerus fractures were operated with open reduction through a Trans-olecranon approach and internal fixation using two plates in inverted-Y configuration. Patients were followed for 3 weeks, 3 and 6 months were evaluated using the Mayo Elbow performance score and Quick-DASH score. There were 50(83.33%) men and 10(16.67%) women with mean age of 34.9±12.63 years. 63.3% of the cases were fol-

lowing Motor vehicle accident and rest following fall. The right upper limb was more commonly affected than the left side. Riseborough and Radin type II fractures accounted for 3.33% of cases; type III fractures accounted for 50% of cases and type IV accounted for 46.67%. Excellent to Good results were seen in almost 80% of cases as per the Mayo Elbow performance score at 6-month follow-up. Quick-DASH scores for the series at 6-month follow-up was on average of 15.96±9.92.<sup>27</sup>

Sanchez-Sotelo et al<sup>28</sup> in the Mayo Clinic introduced a principle-based parallel-plate technique involving the placement of one plate along the medial epicondyle and another on the lateral supracondylar ridges. These robust plates situated on the medial and lateral columns are interconnected through a mechanism resembling an arch, and interlocking screws play a central role as the keystone of this arch structure. Sanchez-Sotelo et al<sup>28</sup> reported that 34-consecutive cases of complex distal humeral fractures utilized a treatment approach that involved the use of two parallel plates. Among these fractures, 26-fell into the AO Type C3 category. The study found that the average range of motion in flexion and extension was 99°, and the average Mayo Elbow Performance Score (MEPS) was 85 points. The results were considered excellent or good in 79.4% of the cases. There was one reported instance of a deep infection, which resolved after the removal of hardware, and 16% of patients required reoperation to address the presence of heterotopic ossification. It's important to note that this study involved multiple surgeons and different implant types, including the Mayo Clinic Congruent Elbow Plate, the Dupont plate by Howmedica, and pelvic reconstruction plates along with dynamic compression plates (DCP) by Synthes. Athwal et al<sup>29</sup> studied 37 patients who had Type C distal humeral fractures and were treated using the bicolumnar parallel plating system revealed that the average range of motion in elbow flexion-extension was 97°, and the average Mayo Elbow Performance Score (MEPS) was 82 points. Theivendran et al<sup>30</sup> retrospectively reviewed 16 patients with

distal humeral fractures treated with the parallel plating technique. The mean flexion was 132° and extension was 29°. Grip strength was 56% of the uninjured side and the mean MEPS score was 72.3.

### Conclusion:

This study concluded that the frequency of satisfactory clinical outcome by using Mayo elbow performance score after elbow reconstruction using two plates in inverted Y configuration for distal humeral intercondylar fracture is quite high. So, we recommend that elbow reconstruction by using two plates in inverted Y configuration for distal humeral intercondylar fracture should be done routinely in our general practice in order to reduce the morbidity of our population.

**Conflict of interest:** None

**Funding source:** None

### Role and contribution of authors:

Muhammad Inam, collected the data, references and did the initial writeup.

Obaidullah Khan, helped in collecting the data and also helped in introduction writing.

Muhammad Saeed, helped in collecting the references and also helped in abstract writing.

Zieshan Faisal, helped in collecting the data and also helped in discussion writing.

Nida Shahid, collected the references and also helped in material and methods writing.

### References:

- Lee SK, Kim KJ, Park KH, Choy WS. A comparison between orthogonal and parallel plating methods for distal humerus fractures: a prospective randomized trial. *Eur J Orthop Surg Traumatol.* 2014;24(7):1123–31.
- Nolan BM, Sweet SJ, Ferkel E, Udofia AA, Itamura J. The role of computed tomography in evaluating intra-articular distal humerus fractures. *Am J Orthop.* 2015;44(9):326–30.
- Medvedev G, Wang C, Amdur R, Neviasser R, Neviasser A. Operative distal humerus fractures in older patients: predictors for early complications based on a national database. *HSS J.* 2017;13(3):212–6.
- Bryan R. Fractures about the elbow in adults. *Instr Course Lect.* 1981;30:200–23.

- Lecestre P, Dupont J. “[Severe fractures of the lower end of the humerus in adults (author’s transl)] *Rev ChirOrthopReparatriceAppar Mot.* 1978;65(1):11–23.
- Dubberley JH, Faber KJ, Macdermid JC, Patterson SD, King GJW. Outcome after open reduction and internal fixation of capitellar and trochlear fractures. *J Bone Joint Surg Am.* 2006;88(1):46–54.
- Muller M, Nazarian J, Koch P. Fracture and dislocation compendium. Orthopaedic Trauma Association Committee for Coding and Classification. *J Orthop Trauma.* 1996;10.
- Wang Y, Zhuo Q, Tang P, Yang W. *Cochrane database of systematic reviews.* Chichester: Wiley; 1996.
- Hausman M, Panozzo A. Treatment of distal humerus fractures in the elderly. *Clin OrthopRelat Res.* 2004;425:55–63.
- Kumar S, Singh S, Kumar D, Kumar N, Verma R. Intercondylar humerus fracture- parallel plating and its results. *J Clin Diagn Res.* 2015;9(1):1–4.
- Kiran GU, Shashidhara H, Manjunath J, Akshay M, Muralidhar A. A prospective study of functional outcome in intrarotational lower end of humerus fracture treated with dual plating. *Int J Orthoped Surg.* 2017;3(3):37–42.
- Li BB, Lin F, Cai LH, Chen Y, Lin ZJ. Meta analysis of parallel versus perpendicular double plating for distal humerus fracture of type C in adults. *Zhonghua Wai Ke Za Zhi.* 2017;55(8):626–31.
- Mahapatra S, Abraham VT. Functional results of intercondylar fractures of the humerus fixed with dual Y-plate; a technical note. *Bull Emerg Trauma.* 2017;5(1):36–41.
- Shaik RB, Reddy VP, Naidu AK. Study of clinical outcome in intra articular distal humerus fractures treated with dual plating. *Int J Res Med Sci.* 2017;5:2438–41.
- Anglen J. Distal humerus fractures. *J Am AcadOrthop Surg.* 2005;13(5):291–7.
- Robinson CM, Hill RMF, Jacobs N, Dall G, Court-Brown CM. Adult distal humeral metaphyseal fractures: epidemiology and results of treatment. *J Orthop Trauma.* 2003;17(1):38–47.
- Kannus P, Niemi S, Parkkari J, Palvanen M, Heinonen A, Sievänen H, et al. Why is the age-standardized incidence of low-trauma fractures rising in many elderly populations? *J Bone Miner Res.* 2002;17(8):1363–7.
- Egol K, Koval K, Zuckerman J. *Handbook of fractures.* Philadelphia: Lippincott Williams & Wilkins; 2010.
- Wang Y, Zhuo Q, Tang P, Yang W. *Cochrane database of systematic reviews.* Chichester: Wiley; 1996.
- Hausman M, Panozzo A. Treatment of distal humerus fractures in the elderly. *Clin OrthopRelat Res.* 2004;425:55–63.
- Korner J, Diederichs G, Arzdorf M, Lill H, Josten C, Schneider E, et al. A biomechanical evaluation of methods of distal humerus fracture fixation using locking compression plates versus conventional reconstruction plates. *J Orthop Trauma.* 2004;18(5):286–93.
- Lee SK, Kim KJ, Park KH, Choy WS. A comparison between orthogonal and parallel plating methods for distal humerus fractures: a prospective randomized trial. *Eur J Orthop Surg Traumatol.* 2013;24(7):1123–31.
- Scolaro JA, Hsu JE, Svach DJ, Mehta S. Plate selection for fixation of extra-articular distal humerus fractures: A biomechanical comparison of three different implants. *Injury.* 2014;45(12):2040–4.
- Schemitsch EH, Tencer AF, Henley MB. Biomechanical evaluation of methods of internal fixation of the distal humerus. *J Orthop Trauma.* 1994;8(6):468–75.
- Bogataj M, Kosel F, Norris R, Krkovic M, Brojan M. Biomechanical study of different plate configurations for distal humerus osteosynthesis. *Med Biol EngComput.* 2015;53(5):381–92.
- Shin SJ, Sohn HS, Do NH. A clinical comparison of two different double plating methods for intraarticular distal humerus fractures. *J Shoulder Elb Surg.* 2010;19(1):2–9.

27. Mahapatra S, Abraham VT. Functional Results of Intercondylar Fractures of the Humerus Fixed with Dual Y-Plate; A Technical Note. *Bull Emerg Trauma*. 2017 Jan; 5(1): 36–41.
28. Sanchez-Sotelo J, Torchia ME, O'Driscoll SW. Complex distal humeral fractures: internal fixation with a principle-based parallel-plate technique. *J Bone Joint Surg Am* 2007; 89: 961-969.
29. Athwal GS, Hoxie SC, Rispoli DM, Steinmann SP. Precontoured parallel plate fixation of AO/OTA type C distal humerus fractures. *J Orthop Trauma* 2009; 23: 575-580.
30. Theivendran K, Duggan PJ, Deshmukh SC. Surgical treatment of complex distal humeral fractures: functional outcome after internal fixation using precontoured anatomic plates. *J Shoulder Elbow Surg* 2010; 19: 524-532.