

## Prosthetic mesh repair of incisional hernia

Muhammad Israr, Nisar Ali, Muhammad Hussain, Hidayat ur Rahman

### Abstract

**Objective.** The objective of this prospective study was to determine the best outcome of incisional hernia treatment taking in to account recurrence, complications and patient's satisfaction.

**Design:** A retrospective study.

**Patients and method:** The study was conducted in the surgical unit of Saidu Teaching Hospital Swat from August 2002 to February 2006. A total number of 50 patients with incisional hernia were evaluated and operated under general anaesthesia. In all patients, polypropylene mesh was used. After general anaesthesia the patient was scrubbed and draped. The previous operation scar was excised then the defect margins was clearly dissected, rectus sheath and muscle also clearly dissected. Then the rectus sheath was incised at a distance from the margin according to the size of the defect so that the lateral margin of the medial leaf of rectus sheath of both side can be approximated over the inverted hernial sac without tension. The medial leaf of the anterior rectus sheath was then elevated and after inverting the sac, the lateral margin of the medial leaf was approximated over the inverted sac and sutured without tension with 2/0 polypropylene. Then the medial margin of the lateral leaf was elevated and the polypropylene mesh was placed over the rectus muscle and was sutured to the under surface of the lateral leaf of rectus sheath.

**Results:** Out of 50 patients with incisional hernia, 33 were women and 17 men. The median age was 58 years for men and 50 years for women. The original incision was midline in 38; transverse in 10 and right lower paramedian in two patients. Thirty nine patients had primary incisional hernia and eleven had a first recurrence of incisional hernia, out of these eleven patients three had a previous attempt of hernial repair with mesh. In 24 patients, the original operation was bowel related, in 16 gynaecological, in 6 biliary surgery, in 3 renal surgery and aortic aneurysm in one. Post operative complication like seroma formation, superficial wound infection and wound haematoma were noted in eight, two and one patient respectively. All patients received antibiotics and analgesic. After three years of follow up, no recurrence was found.

**Conclusion:** We recommend that all defects in the abdominal wall, independent of the size of the defect should be repaired with prosthetic mesh.

**Key words:** Saidu Teaching Hospital, Propylene Mesh, Incisional hernia.

### Introduction:

Incisional hernia is a chronic wound failure and presents some time after surgery. The incidence of incisional hernia is 10-15%; 90% of these occur within three years of surgery<sup>1</sup>. Wound de-

hiscence is an acute wound failure and has an incidence of 1-3%<sup>2</sup>. The risk factor for the development of incisional hernia include obesity, diabetes mellitus, old age, male sex, smoking, emergency surgery, bowel surgery, post opera-

Saidu Medical College  
Swat  
M Israr  
N Ali  
M Hussain  
H U Rahman

**Correspondence:**  
Dr Muhammad Israr  
Assistant Professor of  
Surgery  
Saidu Medical College  
Swat.  
israrsurgeon@yahoo.com

tive wound dehiscence, suture type and technique, and wound infection<sup>3,4</sup>. There is evidence that in many cases, wound failure after abdominal wall closure is dependent on the surgeon's skill<sup>5</sup>. Many of these risk factors are not readily avoidable, but sound surgical technique with appropriate suture material, good bites of tissue (> 1 cm) properly made knots and avoidance of excessive tension is important. If possible, restoring normal anatomy during closure of abdominal wounds should be attempted. Repair of large abdominal incisional hernia is a difficult surgical problem with recurrence being a common outcome. Recurrence rate up to 33% after first repair and 44% after second repair has been reported<sup>6</sup>. For incisional hernia primary closure was the method of choice until the introduction of prosthetic mesh. Presently surgeons tend to use prosthetic mesh in larger defects and primary closure in smaller ones. Mesh repair of incisional hernia have shown favorable results regarding recurrence compared to non mesh repair in several randomized trials and in one controlled randomized trial reported by Leujendijk et al<sup>7</sup>. Numerous method of repair has been described, primary repair in one or two layers, mayo-type overlap, use of fascia (local or flaps) with suture darns and the use of fascia with synthetic mesh (poly propylene or marlex mesh, stainless steel, mersilene or expanded poly tetra fluoro ethylene)<sup>6,8,9</sup>. We describe our experience with technique using fascia and polypropylene mesh. This technique was used by H.S Haira et al in 2001<sup>10</sup>. This technique was initially used in the repair of long midline incisional hernia but subsequently was applied to sub-costal hernia by Whiteley (1998)<sup>11</sup>. In this study we used overlap and two points anchor of the polypropylene mesh.

#### **Materials and methods:**

The prospective study was conducted in surgical unit of Saidu Teaching Hospital Swat from August 2002 to February 2006. The total number of patients in this study were 50. All the operations were performed under general anaesthesia. After cleaning and draping of the abdomen the previous cutaneous scar was excised, incisional hernial sac identified, and dissected from the

margin of the defect, then the margin of the defect cleared. The rectus sheath, rectus muscle and aponeurosis of the external oblique was clearly dissected and exposed around the defect. (figure 1). The sac was opened only in those patients in whom there were history of obstruction or the content of the sac was irreducible, otherwise the sac was inverted. The rectus sheath was incised at a distance from the margin according to the size of the defect, so that the lateral margin of the medial leaf of rectus sheath of both sides can be approximated over the inverted sac without tension. The medial leaf of the anterior rectus sheath was then elevated and after inverting the sac, the lateral margin of the medial leaf was approximated over the inverted sac and sutured without tension with polypropylene 2/0. (Figure 3). In the case of transverse incisional hernia care was taken to ensure that the circumferential incision had apponeurotic or fibrous scar tissue on either side.

In midline incisional hernia, the lateral leaf of rectus sheath was elevated from the rectus muscle and the mesh was put under the elevated margin of rectus sheath. Then the elevated lateral sheath was put over the mesh and anchored with polypropylene suture. In transverse hernia the mesh was placed over the rectus sheath and sutured to the under surface of the external oblique muscle with loose interrupted polypropylene suture (Figure 4).

The medial margin of the lateral leaf was also elevated from the underlying rectus muscle or the fibrous margin of the lateral defect of transverse hernia was then sutured to the upper margin of the mesh with continuous polypropylene to give a tension free repair. One Redivac suction drain was put in and the skin was closed with interrupted nylon suture. All patients received injection ceftriaxone (Rocephin) one gram daily for five days. The drain was removed in most patients after 24 hours and in six patients after 48 hours when there was less than 20 ml of drainage. On first post-operative day all the patients were mobilized. All these patients were followed up to March 2009 in out patients department and after taking a detailed history, a physical exami-

Figure 1: Diagrammatic representation of incisional hernia

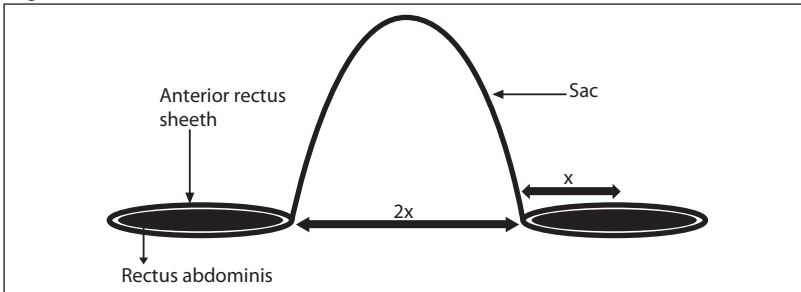


Figure 2: The medial leaf of rectus sheath after division is dissected free and medially elevated

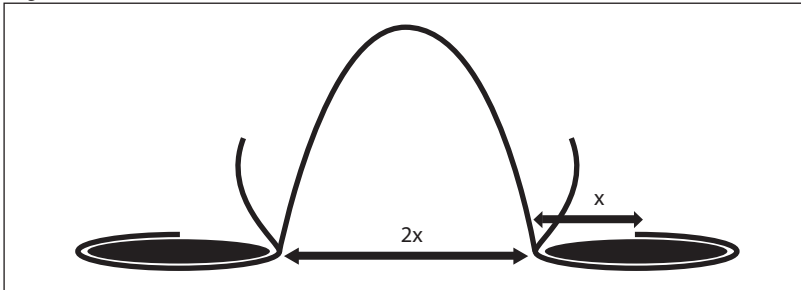


Figure 3: After inverting the sac, the lateral margins of the medial leaf of rectus sheath are sutured in midline. The lateral leaf is dissected and elevated

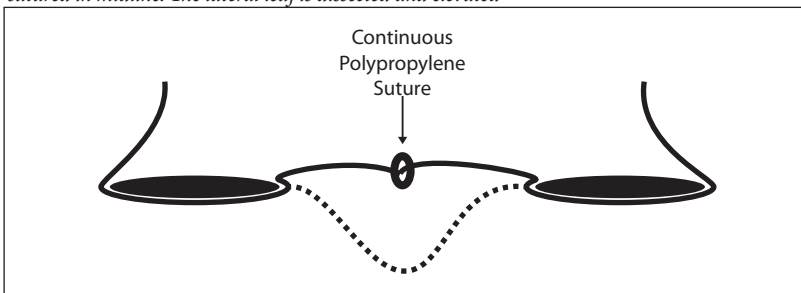


Figure 4: A polypropylene mesh is sutured to the undersurface of external oblique muscle

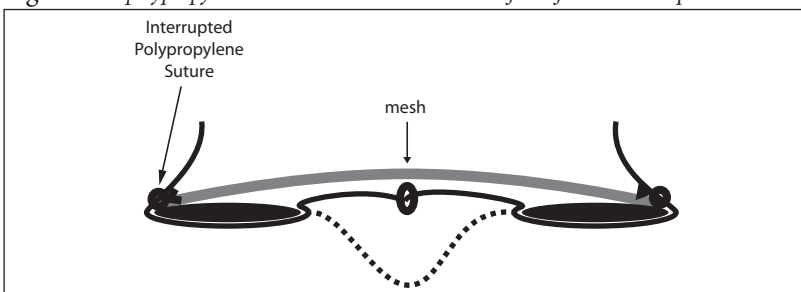
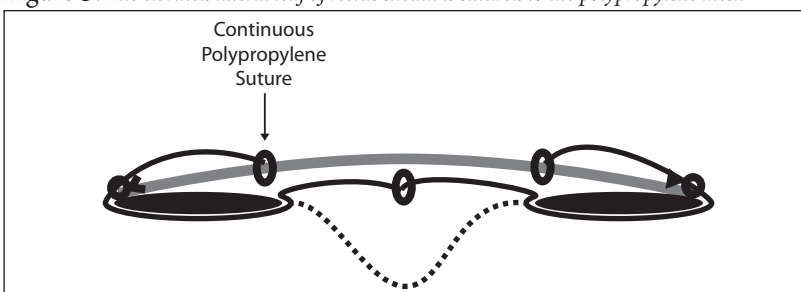


Figure 5: The elevated lateral leaf of rectus sheath is sutured to the polypropylene mesh



nation was performed. The abdomen was examined for hernia recurrence, which was defined as any fascial defect that was palpable or detected by ultrasound examination and was located within 6 cm of the site of hernia repair.

The examination included abdominal palpation in supine position with leg extended and raised. Ultrasound examination was performed when physical examination was inconclusive.

Seventeen men and thirty three women were evaluated. Their median age was 58 years for men and 50 years for women. In 24 patients the original operation was bowel related, in 16 patients gynaecological, six patients had previous biliary surgery, renal surgery in 3 and aortic aneurysm in one patient. The original incision was midline in 38; transverse in 10 and right lower paramedian in two patients. According to the size of the defect, incisional hernia was divided into large, medium and small. Out of these 50 patients, 19 had large, 21 medium and 10 patients had small incisional hernia. Thirty nine patients had primary incisional hernia and eleven had a first recurrence of incisional hernia.

For each patient a proforma was completed, noting the recovery from anaesthesia, per operative and intra operative complications and analgesic requirement.

Follow up of these patients were completed in the out patient department.

**Results:**

Among fifty patients, 39 had primary incisional hernia and eleven had a first recurrence of incisional hernia and out of these eleven, three had a previous attempt of hernia repair with mesh. No intra-operative complication was observed but two female patients were electively ventilated for 24-36 hours because the hernia in these patients was large in size, of long duration and not reducible. Post-operative complication like seroma formation, superficial wound infection and wound haematoma were recorded in 8, 2 and one patients respectively. Seroma formation was the commonest complication and in these

patients. Seroma was aspirated repeatedly. All patients received injection ceftriaxone (Rocephin) 1 gm twice a day for 5 days. Two patients develop superficial wound infection which was treated with appropriate antibiotics after culture and sensitivity. One patient suffered from wound haematoma which was drained. Post-operative hospital stay ranged from 3-8 days. For pain, post-operative injection diclofenac sodium 75mg was given to all patients 8 hourly for 1st and 2nd post operative day regularly and after that, it was given as required. In all fifty patients, wound healing was satisfactory. Among 50 patients 47 were available for follow up and these were followed for three years. One of these patients was not satisfied from the result due to asymmetry of the abdominal wall and disfiguring abdominal scar. Two patients reported mild persistent pain but no recurrence was found in these 47 patients after three years of follow up.

#### **Discussion:**

Before the introduction of mesh, natural tissues were employed to repair large defects of the abdominal wall. The potential of the recent development of plastics for the repair of large hernia was realized more than 50 years ago by Stock<sup>12</sup>. This was the result of casual observation that increasing quantities of fancy shoes with nylon upper were appearing in the Hong Kong market and led him to investigate the use of this material as a potential repair material for hernia. The initial use of this material for hernia repair by Stock was successful. Later on the use of mersilene mesh (braided polyester) for the repair of incisional hernia was reported by Notaras<sup>13</sup>. The technique used by Notaras are still in use today; he implanted the mersilene mesh deep to the rectus muscle (sublay) with its edges at least 2.5cm beyond the edges of the defect and prophylactic antibiotics were administered and close suction drainage was used. In our study we implanted the mesh above the medial leaf of rectus sheath and rectus muscle and below the lateral leaf of rectus sheath. All our patients also received antibiotics and one suction drain was put in the wound. This method has been used for hernias arising from incision other than those in the midline<sup>11</sup>. In our study the original

incision was transverse in 10 patients and lower paramedian in 2 patients. Most incisional hernia is repaired using one of the several techniques that employ mesh. Polypropylene and polyethylene meshes are commonly used. They are flexible and easily cut to size. They allow excellent tissue ingrowth, but they become anchored to adjacent tissues and therefore are not suitable for technique that allow the mesh to come into contact with the abdominal viscera. If this happens, extensive adhesion to the viscera form and erosion of the mesh into the intestine may occur<sup>14</sup>. In our study, we used polypropylene mesh above the rectus muscle and these types of complications were not observed in our patients after three years of follow up.

Mesh repair of incisional hernias showed excellent results regarding hernia recurrence compared to non mesh repair in several non randomized trials and one controlled randomized trial reported by Luijendijk et al<sup>7</sup>. It has been suggested that overlapping leads to a better repair when one considers using fascia alone or in combination with mesh<sup>15, 16, 17, 18</sup>. Liakakos et al carried out a prospective comparison of primary closure against the use of mesh at a mean of 7.6 years follow up<sup>19</sup>. In our study, after three years follow up no recurrence was found. Post operative wound infection is a potentially major complication; luckily it is usually superficial but at times it can be severe enough to necessitate removal of the mesh<sup>20</sup>. In this study 2 (4%) patients suffered from superficial wound infection which was treated with appropriate antibiotics.

Seroma formation was reported to be 4% by Molloy et al, 6% by Lewis et al, and 5.8% by Usher, despite the subcutaneous position of mesh and the extensive dissection involved<sup>16,21</sup>. In our study 4(16%) patients developed seroma. 45% seroma formation was observed whether suction drain was used or not by Jacob et al<sup>22</sup>.

After mesh repair of inguinal hernia 1.6% incidence of seroma formation was reported by Usher and this lower rate suggested by him was due to the deeper position of the mesh<sup>23</sup>. Previous studies have shown that 70-75% of recurrences

develop within 2 years and 80-90% develop within three years<sup>1,2,4</sup>. After three years of follow up, in our study we have not seen recurrence.

### Conclusion:

In our opinion, enough evidence has been obtained to recommend that all defects in the abdominal wall should be repaired with prosthetic mesh. We also strongly recommend that a mesh should be used independent of the size of the defect.

### References:

- Mudge M, Hughes L. Incisional hernia: a 10 years prospective study of incidence and attitude. *Br J Surg* 1985;72:70-1
- Waqar S H, Malik Z I, Razzaq A, Abdullah M T, Shaima A, Zahid M A. Frequency and risk factors for wound dehiscence/burst abdomen in midline laparotomies; *J Ayub Med Coll* 2005;17:70-3
- Wong SY, Kingsnorth AN. Prevention and surgical management of incisional hernia: *Int J Surg Invest*; 2001;3:407-14
- Van't Riet M, de Vos van Steenwijk PJ, Steyerberg EW, Jeekel J. Incisional hernia after repair of wound dehiscence: incidence and risk factors; *Ann Surg*. 2004;70:281-6
- Yahchouchy-chouillard E, Aura T, Picone O, Etienne J-C, Fingerhut A. Incisional hernias; Related risk factors; *Dig Surg*. 2003;20:3-9
- Langer S, Christiansen J. Long term results after incisional hernia repair; *Acta Chir Scand* 1985;151:217-20
- Luijendijk RW, Hop WC, Van den Tol MP, De Lange DC, Braaksma MM, IJzermans JN, Boelhouwer RU, De Vries BC, Salu MK, Wereldsma JC, Bruijninx CM, Jeekel J. A comparison of suture repair with mesh repair for incisional hernia. *N Engl J Med* 2000;343:392-8
- Young D. Repair of epigastric incisional hernia; *Br J Surg* 1961; 48:514-16
- Van der Lei B, Bleichrodt RP, Simmermacher RKJ, van Schilgraffe R. Expanded polytetrafluoroethylene patch for the repair of large abdominal wall defects. *Br J Surg* 1989;76:803-5
- H S Khaira, P Lall, B Hunter and J H Brown. Repair of incisional hernias *J R Coll Surg Edinb* 2001; 46:39-43
- Whiteley MS, Ray-Chaudhuri SB, Galland RB. Combined fascia and mesh closure of large incisional hernias. *J R Coll Surg Edinb* 1998;43:29-30
- Stock FE. Repair of large hernias with nylon mesh. *Lancet* 1954; 1:395-6
- Notaras MJ. Experience with mersilene mesh in abdominal wall repair. *Proc R Soc Med* 1974; 67:1187-90
- David C Bartlett, Andrew N Kingsnorth. Abdominal wall dehiscence and incisional hernia. *Surg International* 2006; 74:234-8
- Usher FC. New technique for repairing incisional hernias with marlex mesh. *Am J Surg* 1979;138:740-1
- Molloy RG, Moran KT, Waldron RP, Brady MP, Kirwan WO. Massive incisional hernia: abdominal wall replacement with marlex mesh. *Br J Surg* 1991;78:242-4
- Adoff M, Arnaud JP. Surgical management of large incisional hernias by an intra peritoneal mersilene mesh and aponeurotic graft. *Surg Gynecol Obstet* 1987;165:204-6
- Hope PG, Caster SStC, Kibly JO. The Da Silva method of incisional hernia repair. *Br J Surg* 1985;72:569-70
- Liakakos T, Karanikas I, Panagiotidis H, Dendrinou S. Use of marlex mesh in the repair of recurrent incisional hernia. *Br J Surg* 1994;81:248-9
- Matapurkar BG, Gupta AK, Agarwal AK. A new technique of!! Marlex-peritoneal sandwich!! in the repair of large incisional hernias. *World J Surg* 1991;15:768-70
- Lewis RT. Knitted polypropylenes (marlex) mesh in the repair of incisional hernias. *Can J Surg* 1984;27:155-7
- Jacobs E, Blaisdell FW, Hall AD. Use of knitted marlex mesh in the repair of ventral hernias. *Am J Surg* 1965;110:897-902
- Usher FC. Hernia repair with marlex mesh. An analysis of 541 cases. *Arch Surg* 1962;84:73-6
- Read RC, Yoder G. Recent trends in the management of incisional herniation. *Arch Surg* 1989;124:485-88