

## CASE REPORT

## Communication between radial nerve and medial cutaneous nerve of forearm

RR Marathe, Sumedha R Mankar, Manoj Joshi, Yogesh A Sontakke

### Abstract:

**Radial nerve is a branch of posterior cord of brachial plexus. It innervates Triceps, Anconeus, Brachialis, Brachioradialis, Extensor carpi radialis longus muscles and gives the posterior cutaneous nerve of arm, lower lateral cutaneous nerve of arm, posterior cutaneous nerve of forearm without exhibiting any communication with medial cutaneous nerve of forearm or any other nerve. Here, a communication between radial nerve and medial cutaneous nerve of forearm on left side is reported in an adult male cadaver. Right sided structures were found to be normal. Neurosurgeons should keep such several variations in mind while performing surgeries of axilla and upper arm.**

**Key Words:** radial nerve, medial cutaneous nerve of forearm.

### Introduction:

As per medical and surgical aspects, nerve supply of arm is very important. The brachial plexus is the network formed by the communications between the anterior rami of the fifth to eighth cervical nerve roots and first thoracic nerve root. Almost every muscle of the upper limb is supplied by nerves derived from the brachial plexus, as is most of its overlying skin. The radial nerve is a terminal branch of the posterior cord of the brachial plexus. It is the largest branch of the plexus, supplying the majority of the posterior and extensor components of the arm and forearm. The medial cutaneous nerve of forearm arises from the medial cord of the brachial plexus, initially lying between the axillary artery and vein. A ramus breaches the deep fascia to supply the skin overlying biceps. Travelling distally, it lies medial to the brachial artery, and pierces the deep fascia at the midpoint of the upper arm adjacent to the basilic vein. Here it divides into two branches. The anterior branch passes anterior to the median cubital vein. It lays anteromedially in the forearm and supplies skin of the wrist. The posterior branch has an oblique course anteriorly, lying medial to the basilic vein, becoming posterior distal to the medial epicondyle of the humerus to descend on the posteromedial bor-

der of the forearm towards the wrist. It supplies a smaller area of the posteromedial forearm<sup>1</sup>.

Although communications between the nerves in arm are rare, the communication between Median nerve and Musculocutaneous nerve was described since 19th century<sup>2</sup>. Anatomical variations of peripheral nerves are important to medical personnel especially to orthopedic surgeons, neurophysicians, physiotherapist and radiologists. Such comprehension is useful in nerve grafting, neurophysiological evaluation for diagnosing peripheral neuropathies. Present variation was observed during routine dissection at the Anatomy Department of Jawaharlal Nehru Medical College, Sawangi.

### Case Report:

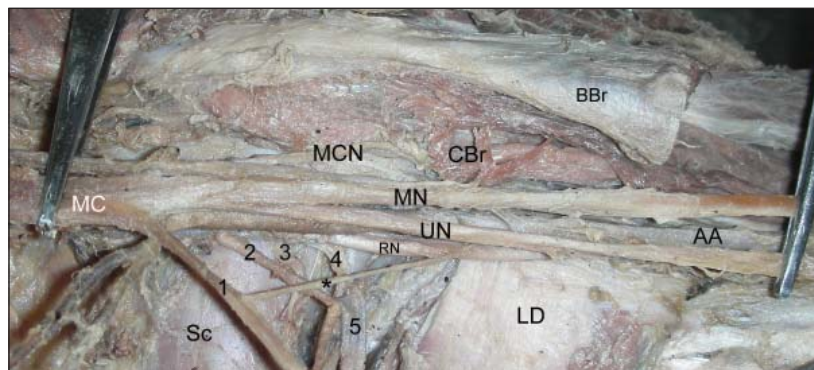
In an adult male cadaver, Brachial plexus was exposed after excising Pectoralis major and Pectoralis minor muscle. Fat was cleared carefully to obtain clear view of contents of axilla. A communication between radial nerve and medial cutaneous nerve of forearm on left side was found (Figure). The communicating nerve was found to be arising from medial cutaneous nerve of forearm. The communicating nerve was crossing third part of axillary artery on its medial side

**Department of Anatomy,  
Jawaharlal Nehru  
Medical College, Sawangi  
(Meghe), Wardha, M.S.,  
India.**

RR Marathe  
S R Mankar  
M Joshi  
Y A Sontakke

### Correspondence:

Dr. Yogesh A Sontakke  
In charge, Cytogenetics,  
Asst. Professor,  
Department of Anatomy  
J N Medical College,  
Wardha- 442004, M.S.,  
India  
Phone: +91-9881013826  
dryogeshas@rediffmail.  
com



**Figure:** Axillary dissection showing communication between radial nerve and medial cutaneous nerve of forearm. (AA: Axillary artery; BBr: Biceps brachii; CBr: Coracobrachialis; LD: Latissimus dorsi; MC: Medial cord; MCN: Musculocutaneous nerve; MN: Median nerve; RN: Radial nerve; SC: Subscapularis muscle; UN: Ulnar nerve; \*: Communication between radial nerve and medial cutaneous nerve of forearm; 1: Medial cutaneous nerve of forearm; 2: nerve to Latissimus dorsi; 3: Lower subscapular nerve; 5: Subscapular region)

and found to be running downward, backward and laterally to join radial nerve. This nerve was related medially with axillary vein and laterally to axillary artery and ulnar nerve. Right sided structures were found to be normal.

#### Discussion:

In this case report, we report a communication between radial nerve and medial cutaneous nerve of forearm on left side in an adult male cadaver. Right sided structures were found to be normal. Many researchers have reported communications of radial nerve with other nerves in axilla. Masahiro et al reported communications between radial nerve and axillary nerve in 8 brachial plexus out of 602 plexuses<sup>3</sup>. Marios et al reported the presence of communications between the radial and ulnar nerves on the dorsal surface of the hand<sup>4</sup>. However, the development into the cutaneous branches has no distinct inclination.

The existence of this variation described in our case report may be attributed to the random factors influencing the mechanism of formation of limb muscles and the peripheral nerves during embryonic life. In the context that ontogeny recapitulates phylogeny; it is possible that the variation seen in the current study is the result of developmental anomaly. In humans forelimb muscles develop from mesenchyme of paraxial mesoderm in the fifth week of intrauterine life<sup>5</sup>.

The radial extensor muscles of forearm have a different origin from other extensor muscles of forearm. Regional expression of five Hox D (Hox D 1 to Hox D 5) genes is responsible for upper limb development<sup>6</sup>. The motor axons arrive at the base of limb bud; they mix to form brachial plexus in upper limb. The growth cones of axons continue in the limb bud<sup>5</sup>. The guidance of the developing axons is regulated by the expression of chemo-attractants and chemo-repulsant in highly coordinated site specific fission. The tropic substances attract the correct growth cones or support the viability of the growth cones that happen to take the right path. Tropic substances include brain-derived neurotrophic growth factor, c-kit ligand, neutrin-1, neutrin-2 etc.<sup>7</sup> Significant variations in nerve pattern may be result of altered signaling between mesenchymal cells and neuronal growth cones or circulatory factors at the time of fission of brachial plexus cords.

#### Clinical significance:

Meticulous knowledge of possible variations of Medial Cutaneous Nerve of Forearm and the Radial Nerve may endow help in the trauma management of shoulder joint, arm as well as in circumventing iatrogenic damage during repair operations of these regions.

#### References:

1. Standring S, Borley NR, Collins P, Crossman AR, Gatzoulis MA, Healy JC, Johnson D, Mahadevan V, Newell RLM, Wigley CB. Gray's Anatomy. Pectoral region, shoulder region and axilla. 40th Ed. Churchill Livingstone, London. 791-822, 2008.
2. Linell EA. The distribution of nerves in the upper limb, with reference to variability and their clinical significance, *Journal of Anatomy* 55:79-112, 1921.
3. Masahiro K, Katsushi K, Satoshi M, Keishi O, Kodo K. Communication between the axillary and radial nerves in the human upper arm. *Ann Anat* 1999; 181 (2): 213-221. doi:10.1016/S0940-9602(99)80011-9.
4. Marios L, Robert GL, Christopher TW, Shane TR, Senem TO, Jessica K. The clinical anatomy of the communications between the radial and ulnar nerves on the dorsal surface of the hand. *Surg Radiol Anat* 2008; 30 (2): 85-90.
5. Moore KL, Persaud TVN. Before we are born. 7th Ed. The musculoskeletal system. Saunders Elsevier, Philadelphia. 243-244, 2003.
6. Morgan BA, Tabin C. Hox genes and growth: early and late roles in limb bud morphogenesis. *Development (Suppl)* 181, 1994.
7. Larson WJ. Human Embryology. Development of peripheral nervous system. 3rd Ed. Churchill Livingstone, Pennsylvania. 115-6, 2001.