

## Single port laparoscopic cholecystectomy improves cosmesis

Saleem Khan, Zakiuddin G Oonwala

### Abstract:

**Objective:** Laparoscopic surgery is a constantly evolving field of surgery. Initially started by gynaecologists now gradually taken by general surgeons. Laparoscopic surgery shown proven benefits over open surgery in terms of cosmesis, short operative time, shorter stay in the hospital, cost effectiveness and less requirement of postoperative analgesia. Single port laparoscopic surgery is further modification of laparoscopic surgery. The added advantage is single incision, therefore lesser trauma, lesser pain and analgesia requirement. We have performed single incision laparoscopic cholecystectomy via umbilical approach and an incision of approximately 18-20 mm in size given via umbilicus which easily admitted two fingers. After retracting the fundus via proline suture routine laparoscopic cholecystectomy performed.

**Study Design:** Descriptive case study.

**Setting and duration:** This study was carried out at Hamdard University Hospital and other private hospitals of Karachi from March 2009 till March 2010.

**Methodology:** Twelve cases were operated during this period using the above techniques.

**Results:** Twelve patients underwent single incision laparoscopic cholecystectomy via a standard 20m.m. incision via umbilicus. In all cases covedian single port device was used. In only one case a 5m.m. extra port was required to place in order to retract liver.

**Conclusion:** Single port laparoscopic cholecystectomy is a good alternative to conventional four port laparoscopic cholecystectomy.

**Keywords:** Single incision cholecystectomy, laparoscopic cholecystectomy, single-port cholecystectomy

### Introduction:

Historically the open surgery was the main stay of general surgery but over the years newer procedures were evolved and the surgery is becoming less invasive with smaller incision and cosmetic scars. In the late 1980 the laparoscopic surgery took off but initially this surgery has lot of criticism but now the laparoscopic surgery is the gold standard for billiary surgery, barriatic surgery.

The laparoscopic technology was introduced in the past by Kelling with celioscopy<sup>1</sup>.

A number of gynaecologists kept on performing tubal ligation using laparoscopic technique. With

the advent of video laparoscope and improved instrumentation, laparoscopic surgery was applied to larger cases in general surgery such as cholecystectomy. Several types of procedures have been performed via single port surgery mostly reported in the urological literature<sup>2,3</sup>. The eventual acceptance was due to the persistence of surgeons such as McKernan, Saye, Reddick and Olsen with dedication to teaching and proving patient benefits<sup>4</sup>. Now laparoscopic cholecystectomy has proved beneficial in patient recovery. The procedure became the gold standard for billiary and barriatric surgery.

Many surgeons have suggested modification in the technique but have failed to prove added

Department of Surgery,  
Hamdard University  
Hospital, Karachi  
S Khan  
ZG Oonwala

**Correspondence:**  
Prof Saleem Khan  
Dept of Surgery,  
Hamdard University  
Hospital, Karachi  
Cell: 0333-2233631  
saleem\_deshmukh@  
hotmail.com

benefits. SILS (Single incision laparoscopic surgery) was described as early as 1992 by Pelosi et al<sup>5</sup> who performed a single puncture laparoscopic appendectomy, and in 1996 by Novara et al<sup>6</sup> who performed a laparoscopic cholecystectomy via a two trans umbilical trocars and three trans abdominal gall bladder stay sutures.

Similarly, in 1999 Piskin G, Rajpal S et al showed that multiple trocars could be placed through a single skin incision to perform the same operation. This came to be called single incision laparoscopic surgery<sup>7</sup>.

Navara listed the lack of benefits and reasons, he felt the procedure would not develop<sup>8</sup>.

More recently, Kumar S Agrawal et al reported three port laparoscopic cholecystectomy with good outcome<sup>9</sup>. Newer techniques like NOTES (Natural Orifice Transluminal Endoscopic Surgery) have been performed in the porcine model removing the Gall bladder transvaginally or transgastrically<sup>10</sup>.

The benefits of the above technique is speedy recovery, less duration of anesthesia and excellent cosmesis. The hazards of the above procedure especially in transgastric removal of bladder may be associated with risk of unacceptable risk of leak and infection.

Hirano et al,<sup>11</sup> published his paper in issue 2 volume 16 of World J. Gastroenterol 2010 in which he suggested use of loop to retract Gall bladder, this avoids perforation of the gall bladder & unnecessary spillage of bile in the peritoneal cavity. This method increases the safety of the procedure but in purist term, makes it double incision laparoscopic surgery, DILS.

Scar less surgery and decrease requirement of port operative analgesia resulted in the emergence of a new approach using single incision with multiple instruments entering through a single port device<sup>12,13</sup>.

In April 2007, Podolsky ER et al. reported the first case of single port access<sup>14</sup>. He developed

this unique access technique utilizing the basic principle of current laparoscopic surgery and standard instrumentation and access device. Although single port laparoscopic cholecystectomy has previously been described in the literature, the evaluation of the utility of this procedure is limited to patient selected case series.<sup>15</sup>

Unlike prior published case series Cuessta MA, Berends F et al showed in their series that they have performed single port laparoscopic cholecystectomy on all types of biliary diseases including acute cholecystitis with inflammation.<sup>16</sup>

We used single port access technique at our centre using covideon single port access device as shown in the figure 1. We used one 10mm port using same covideon device as shown in figure 2.

#### **Methodology:**

This is a descriptive study carried out at Hamdard University Hospital and other private Hospitals from March 2009 till March 2010. All 12 patients were female patients, the average age was 35 years ranging from 22 to 46 years. All the patients were evaluated one week post-operatively, then a month, three months and a year. These patients were evaluated for complications like incisional hernia.

#### **Inclusion and exclusion criteria:**

All cases of cholelithiasis who fulfill the criteria of ASA 1 & 2 (American Society of Anaesthesiologists) were included in the study. The cases with a known history of obstructive jaundice, CBD stones, pancreatitis, obesity and acalculus cholecystitis were excluded from the study.

#### **Procedure:**

A midline 18-20 mm incision given via the umbilicus. Linea alba identified and access to the peritoneum gained under direct vision. Two fingers were easily placed in the incision. Covideon single port used in all cases and CO<sub>2</sub> insufflations done as shown in figure 3. Gall bladder was hooked after placing a stitch using "O" Prolene on straight needle as shown in figure 4. A curved reticulated grasper applied at Hartman's

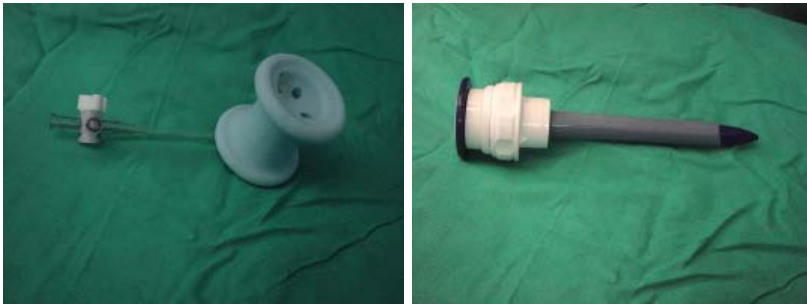

Figure 1: The Single Port Device with permission from M/s Covideon. Figure 2: 10 mm Port for use of telescope

pouch to open Callot's triangle. Telescopes of both 0° and 30° were used. Cystic duct and cystic artery visualized using curved reticulated Maryland forceps and clip applied around cystic duct and cystic artery which was eventually divided between clips. Gall bladder separated from the liver bed using diathermy hook.

**Results:**

Twelve patients under went single incision cholecystectomy via a standard 18-20 mm incision via the umbilicus using Covideon single port device. All cases carried out without any complications. In one case another 5m.m. port was inserted to retract liver.

Initially our operation time was 2 hours but gradually we were able to bring it to 75 minutes (Figure 5). The average operation time was 85 minutes in the study. Mean hospital stay was 22 hours ranging 16 hours to 32 hours (Figure 6).

**Discussion:**

We have been using single incision surgery as an alternative approach to four port standard laparoscopic surgery. The advantages of single port are both to surgeons and patients, offering increased surgeon comfort, improved cosmesis and possibly quicker recovery and decreased

pain also quoted by Erica R. Podalsky et.al<sup>14,15</sup>.

Arun Parsad<sup>17</sup> in his study of 40 single incision laparoscopic surgery used conventional trchars, instruments and telescope to avoid increase in the cost that is inevitable if we use reticulating instruments and more expensive semiflexible laparoscope or special ports.

The similar experience is being shared by Romanelli JR, Mark L et.al<sup>18</sup>.

For single port laparoscopic surgery different surgeons have different views regarding insertion of the trocars. Few suggested inserting trocars in triangular manner with a 10m.m. telescope inserted from the top port to avoid sword fighting of instruments. The lower 5m.m. ports are manipulated by "Chop and Stick method" so that they did not collude.

There is uniform agreement that after the first 20 cases, the instruments clashing air leak and duration of surgery reduced which suggest that there is a long learning curve in this procedure<sup>19</sup>.

We also do not have long term results but our

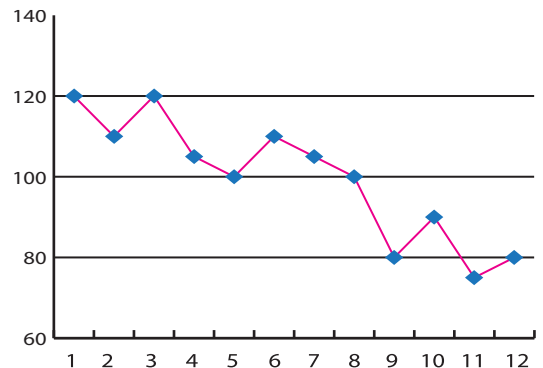


Figure 5: Operative time of single incision laparoscopic cholecystectomy in this study

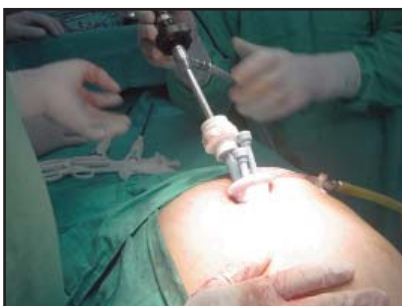


Figure 3: The telescope in position for Single Port Laparoscopic surgery

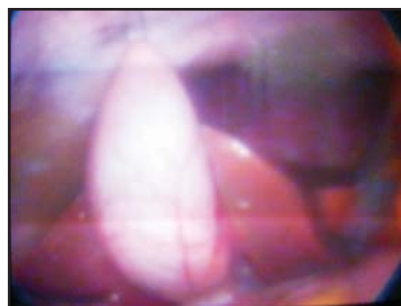

Figure 4: Abdominal view of single port laparoscopic surgery; the gall bladder is put in traction using 0 proline stitch

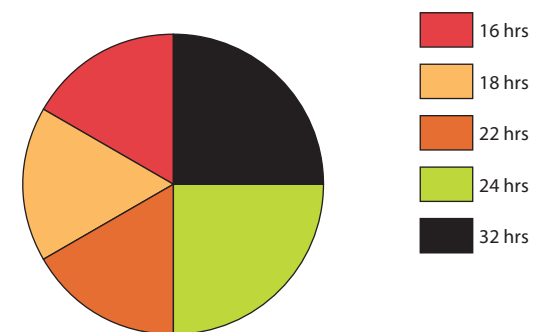


Figure 6: Hospital Stay of our patients

initial result is comparable to that of standard multiple incision laparoscopic cholecystectomy with slightly longer operative times attributed to learning curve.

Cosmesis is improved with a single incision, as scar of single incision almost hidden within the fold of umbilicus as shown in the figure 7. Closure must be done carefully in layers and extended follow up is necessary to address the concern about umbilical hernia development.

Podolsky ER, Rotman SJ et.al<sup>15</sup> performed reduced trochar laparoscopic procedures with articulating instruments with good results and mentioned that with the improvement in the skill and comfort with the articulating instruments. They started using trochar via umbilicus and move them more efficiently.

In our study we use proline stitch to retract gall bladder posterosuperiorly and used an articulated grasper to hold Hartman's pouch to open Callot's triangle and the remaining dissection was done using Maryland forcep. After clear identification of cystic duct, cystic artery clip applied and cystic duct and artery divided and gall bladder was dissected from its bed using diathermy hook.

Strasberg SM, Herd M et.al in their study mentioned that they have used an additional port to retract gall bladder cephalad and inferolaterally to expose the classical described critical view<sup>20</sup>.

### Conclusion:

Single port laparoscopic cholecystectomy is a good alternative to conventional four part laparoscopic cholecystectomy. It improves cosmesis, shorter stay in the hospital and early resumption of work. Its scar becomes almost invisible scar on 4th week and also results in less hospital stay.

The operating time is increased but after long learning curve, is almost same as four port conventional laparoscopic cholecystectomy.

### References:

- Schollmeyer T, Soyinka AS, Schollmeyer M et al. Georg Kelling (1866-1945). The root of modern day minimal invasive surgery. A forgotten legend? Arch Gynecol Obstet. 2007;276:505-509.

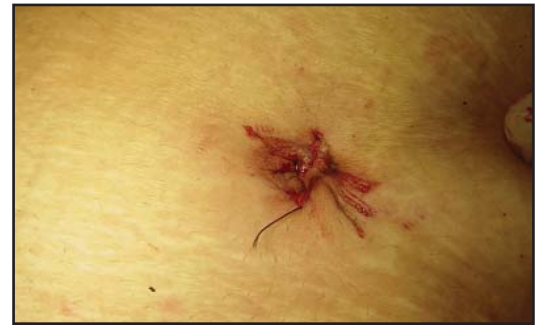

Figure 7: The umbilicus soon after subcuticular closure at the end of the operation

- Rane A., Rao P. et al single port access nephrectomy and other laparoscopic urologic procedure using a novel laparoscopic port (R. Port) urology 2008 2(2);260-264.
- Desai M M, Rao P P Aron M et al. scarless single port transumbilical nephrectomy and pyeloplasty first clinical report BJT. Int 2008; 101; 83-88.
- Podolsky ER, Rottman SJ, Curcillo PG. Single Port Access (SPA) cholecystectomy: two years follow up. JLS 2009;13:528-535.
- Pelosity MA, Pelosity 3rd. Laparoscopic appendectomy using a single umbilical puncture minilaparoscopy. J Reprod Med 1992 37:588-594.
- Navarra G, Pozza E, Occhionorelli S et al. One wound laparoscopic cholecystectomy. Br J Surg 1997; 84:695.
- Pisken E, Rajpal S. Transabdominal laparoscopic cholecystectomy utilizes no incision outside the umbilicus J. laparoendosc Adv Surg Tech. 1999; 9:361-364.
- Navarra G, LaMalfa G, Baroletta C, Curro G. The invisible cholecystectomy, a different way. Surg. Endosc.2003; 22:2103.
- Kumar M, Agrawal CS, Gupta RK. Three-port versus standard four-port laparoscopic cholecystectomy: a randomized controlled trial in a community-based teaching hospital in Eastern Nepal. JLS. 2007;11(3):358-362.
- de la Fuente SG, Demaria EJ, Reynolds JD et al. New developments in surgery: Natural Orifice Transluminal Endoscopic Surgery (NOTES). Arch surg. 2007; 142: 295-297.
- Hirano Y, Manta Watanabe T, Uchida T. et al. Single incision laparoscopic cholecystectomy single institution experience and literature review World J. Gastroenterol 2010 16 270-274.
- Athinos JN, Forrester GJ, Binerbaum SJ, Harvey EJ, Kim GJ, Teixeira JA. Single-incision laparoscopic cholecystectomy using flexible endoscopy: saline infiltration gallbladder fossa dissection technique. Surg Endosc. Epub.????
- Teixeira J, McGill K, Binerbaum S, Forrester G. Laparoscopic single-site surgery for placement of an adjustable gastric band: onitail experience. Surg Endosc. 2009;23(6): 1409-1414. Epub 2009 March 14.
- Podolsky ER., Rottman SJ, King SA., Curcillo 11 PG. Single port access surgery (SPA) gastrostomy tube in patients unable to receive percutaneous endoscopic gastrostomy placement. Surg Endosc. 2009;23(5):1142-1145. Epub 2009 Mar 5.
- Podolsky ER., Rottman SJ, King SA., Curcillo 11 PG. single port Access (SPA surgery) cholecystectomy: a completely transumbilical approach J. laparoendosc Adv Surg Tech. 2009;19(2):219-222.
- Cuesta MA, Berends F, Veenof A. A. the invisible cholecystectomy; u transmbilical laparoscopic operation without a scar surg endosc; 22(5) 1211-1213 May 2008.
- Arun Prasad single incision laparoscopic surgery World J. Gastroenterol 2010 June 7. 167 (21) 2705-2706.
- Romanell JR Mark L. Omotosho PA single port laparoscopic cholecystectomy with triport system a case report surg innvo 2008;15;223-228.
- Brody F vaziri K kaszaJ. Edwards C single incision Laparoscopic Cholecystectomy J Am Coll Surj 2010;210 eq-e13.
- Strasberg SM, Hertl M, Soper NJ. Analysis of the problem of biliary injury during laparoscopic cholecystectomy J. Am Coll Surg. 1995;180:101-105.