

## Frequency of complications in the Snodgrass repair and its risk factors

Tariq Iqbal, Nasir Uddin, Mansoor Khan, Shazia Naz

### Abstract:

**Objectives:** To determine the frequency of complications in the Snodgrass repair for hypospadias and its risk factors.

**Study design:** Descriptive cross-sectional

**Setting:** Department of Plastic and Reconstructive Surgery, Hayatabad Medical Complex, Peshawar from April 2009 to March 2010.

**Material and Methods:** A total of 33 patients having hypospadias (mid-shaft and distal to mid-shaft) were included with the age ranging from 3-28 years. Patients with Ambiguous genitalia, previously operated cases and those who did not agree to enter the study were excluded. Patients were diagnosed on history and local examination. Snodgrass repair was performed by a single surgeon. The patients were followed up for six months to see the development of post-operative complications. Data were analyzed with the help of Statistical package for Social Sciences version 17 and presented in the form of tables and charts.

**Results:** In the current study the frequency of early complications after Snodgrass repair was 12.1% and the frequency of late complications was 36.4%. Most common complication was urethrocutaneous fistula with 27.3%. Early complications noted were edema in 6.1%, surgical site infection in 3% and catheter blockage in 6.1%. Late complications were fistula in 27.3% patients and meatus abnormality in 12.1% of the patients. The distal penile hypospadias patients had the highest frequencies of both early (9.1%) and late (18.9%) complications. Operation time was significantly higher in age group <5 years (p-value = 0.469 with a confidence level of 95%). The frequency of urethrocutaneous fistula was significantly higher in < 5 years age group (p-value of 0.475 with a confidence level of 95%).

**Conclusion:** Urethroplasty using the Snodgrass technique is a single stage repair that may be used for distal hypospadias. It has an acceptable complication rate.

Department of Plastic &  
Reconstructive Surgery,  
Hayatabad Medical  
Complex, Peshawar  
T Iqbal  
M Khan  
S Naz

Civil Hospital, Karachi  
Nasir Uddin

### Correspondence:

Dr. Tariq Iqbal  
House No. 145, street No.  
3, Sector: C-2,  
Phase 5, Hayatabad,  
Peshawar.  
+92 3339234925,  
drkhantariq@yahoo.com

**Keywords:** Hypospadias, Snodgrass, Fistula, Single stage repair.

### Introduction:

The word "hypospadias" is derived from the Greek words hypo, which means below, and spadon, which means rent or hole. Hypospadias is a common congenital anomaly of the penis with an incidence of about 1 in 300 live male births<sup>1</sup>. There is wide variation in the incidence of hypospadias<sup>2</sup>. Hypospadias has some associated abnormalities of abortive development of the urethral spongiosum, the ventral prepuce (dorsal hood) and in more severe cases penile chordee (an abnormal ventral curvature of the

penis). This chordee is due to the difference in length between the ventral and the dorsal side of the penis (corporocavernosal dysproportion). The ectopically positioned urethral meatus lies proximal to the normal site and on the ventral aspect of the penis, and in severe cases opens onto the scrotum or perineum. The form and extent of malformation of the urethral opening varies as well and is in some cases widely gaping and resembling the mouth of a fish. In over 80% of cases the abnormal urethral opening is located distal to the midshaft<sup>3</sup>. Histologically, the

urethral plate consists of well-vascularised tissue with large endothelial sinuses lined around an abortive urethral spongiosum. Fibrosis and cicatrization are rarely present<sup>4</sup>. Approximately 8% to 10% of boys with hypospadias have cryptorchidism and 9% to 15% have an associated inguinal hernia<sup>5</sup>. The etiology of hypospadias remains unknown with environmental exposure in the form of endocrine disruptors the most likely explanation for the worldwide increase in the last three decades<sup>6</sup>. Interferences in the androgen metabolism, for example, 5 $\alpha$ -Reductase deficit, defects of the androgen receptor, or gene defects are possible aetiological factors for hypospadias, that are only found in <5% of the patients<sup>7,8</sup>. Hypospadias is also found as a part of different syndromes. Screening for a urinary tract anomaly by renal ultrasonography should be considered in patients with posterior hypospadias and in those with an anomaly of at least one additional organ system. In patients with cryptorchidism or ambiguous genitalia karyotyping should be considered<sup>9</sup>.

The sequential steps for the successful repair of hypospadias are orthoplasty (penile straightening), urethroplasty, meatoplasty, glanoplasty, scrotoplasty and skin coverage, all preferable in one stage<sup>6</sup>. The major technical advances in hypospadias surgery that have improved surgical outcomes are preservation of the urethral plate, incision of the urethral plate, dorsal midline plication, de-epithelized urethroplasty, dartos flap coverage, and two stage alternative techniques<sup>6</sup>. More than 300 different procedures are performed for hypospadias repair and newer one introduced each year<sup>10</sup>. Numerous procedures described for hypospadias reconstruction are evidence to both surgical ingenuity and dissatisfaction with solutions. The various methods of reconstructing the hypospadiac urethra are the MAGPI repair, Mathieu's repair, Preputial island flap urethroplasty method and the Snodgrass. The Snodgrass technique presents the procedure of choice for distal hypospadias<sup>11</sup>. In fact hypospadias surgery carries very high complication rate even in experienced hands<sup>12</sup>. Complication rate depends on the severity of the anomaly<sup>13</sup>. So far the commonest complication has been

fistula formation<sup>14</sup>. Urethral stricture, scarring, Chordee and painful erection are other trades off from various surgical procedures<sup>14</sup>.

Presently the goals of hypospadias repair are not just to create a straight penis that is adequate for sexual intercourse, to reposition the urethral meatus to the penile tip to allow the patient to void while standing, to create a neo-urethra of adequate and uniform caliber but also an aesthetically acceptable penis with a slit like vertically located meatus. Although some very good functional as well as cosmetic results have been reported with AB (Aivar Bracka) repair, basic problem with this technique is its two steps<sup>14</sup>. In 1994 Snodgrass introduced his technique fulfilling all the goals that is excellent functional and cosmetic results in a single stage<sup>3</sup>. Since then this technique has gained steady popularity worldwide. Impressed with excellent published results we started this technique in our unit. As hypospadias repair has long learning curve<sup>14</sup>, the purpose of this study is to evaluate complication rate of Snodgrass repair for hypospadias in our setup.

#### Material and Methods:

This descriptive cross sectional study was conducted in the department of Plastic and reconstructive surgery of Hayatabad Medical Complex Peshawar from April 2009 to March 2010. All those patients of 3 year of age or above with hypospadias (midpenile, distal penile, subcoronal, coronal and glanular), normal healthy urethral plate and mild Chordee were included. Patients with Ambiguous genitalia, previously operated for Hypospadias and those who did not agree with the study protocol were excluded from the study as they may act as confounders and introduce bias to the results. All the patients were admitted through outpatient department or referral, investigated and prepared for Snodgrass repair. Informed consent was taken from all patients or their parents (as applicable) after explaining the study protocol. Patients were interviewed by taking a detailed history and examined for exclusion criteria. Chordee was evaluated by HOSE (Hypospadias objective Scoring system) to differentiate between mild,

moderate and severe. Pre operative photograph was taken. Pre-operative single dose of injectable antibiotics was given followed by 5 days of oral antibiotics. All the cases were operated by a single experienced (with 5 year post-fellowship experience) surgeon. All the hypospadias were repaired with Snodgrass repair by making parallel longitudinal incisions brought around the meatus, parallel incision of the urethral plate from the native meatus to the tip of the glans, multi-layer closure of the tube, coverage of the tube with mobilized subcutaneous tissue, glansplasty and skin coverage. Urethroplasty was performed only after confirmation of a straight penis by artificial erection. All hypospadias repairs were performed over silicon catheter (size 8Fr or above) and were left in situ for 7th post-operative day. Postoperative All the patients were followed for six months and photographed. Post-operative complications (early complications: haemorrhage, edema, wound dehiscence, and infection, Late complications: urethrocutaneous fistula, urethral stricture, residual chordee and meatal abnormalities) were recorded in a specialized proforma constructed with the help of a statistician.

The data were organized and analyzed using Statistical Package for Social Sciences (SPSS version 17) and the results were expressed in the form of tables and graphs.

**Results:**

**Study population:** A total of 33 patients were studied in this study. The age range was 3 years to 28 years with a mean age of 8.33+5.44 (Fig: 1). Six patients (18.2%) had positive family history for hypospadias and 8 (24.2%) patients had positive consanguinity. Sixteen patients (48.5%) had distal penile hypospadias while 8 patients (24.2%) had coronal hypospadias (Fig: 2). All of the patients had adequate penile size for age, 4 patients (12.1%) were already circumcised while 29 patients (87.9%) were uncircumcised. Pre-operatively 8 patients (24.2%) had meatal stenosis and 4 patients (12.1%) had mild degree of chordee. We did not observe any kind of associated anomaly in our study population.

**Duration of surgery and hospital stay:** The range of duration of surgery was 60 minutes to 90 minutes with a mean duration of 70.24 minutes +9.56 (Fig: 3, Table: I). The hospital stay was from 1-3 days (mean=1.94+0.35). In age group of < 5 years 66.7% (n=8) cases' operation time was above 60 min while in >5 years age 47.6% (n=10) operation time was >60 minutes which is found to be statistically significant with a p-value of 0.469 with a confidence interval of 95% (calculated by Fisher's Exact test).

**Early complications:** Out of the total 33 patients, 4 patients (12.1%) developed early complications. Two patients (6.1%) complicated with post-operative oedema, two patients (6.1%) presented with urinary retention due to catheter blockage. The distribution of early complications in different age groups is presented in figure 5. None of the patients whose operation time was < 60 minutes developed post-operative oedema while 9.5% (n=2) patients developed post-operative oedema in those patients whose operation time was more than 60 minutes with a p-value of 0.523 with confidence interval of 95%

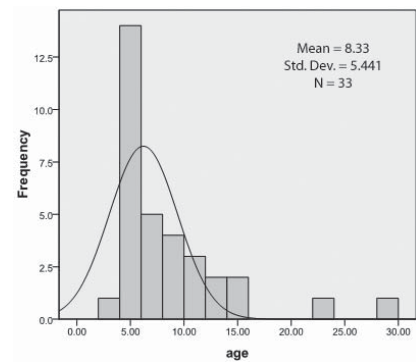


Figure 1: Age distribution of the study population

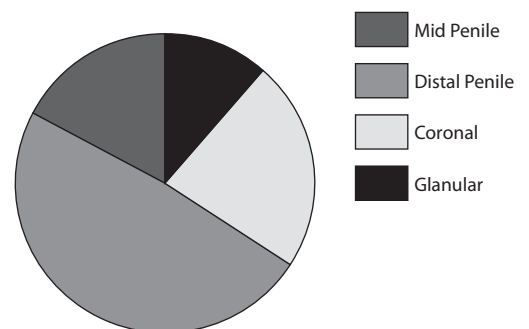


Figure 2: Classification of hypospadias

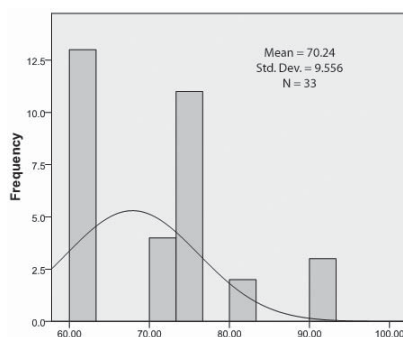


Figure 3: Duration of surgery histogram

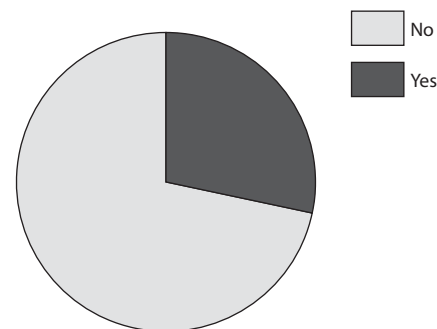


Figure 4: Urethrocutaneous fistula pie chart

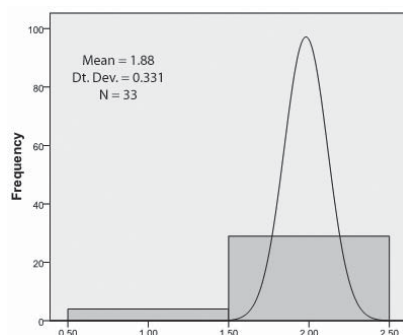


Figure 5: Post-surgical Meatal abnormality

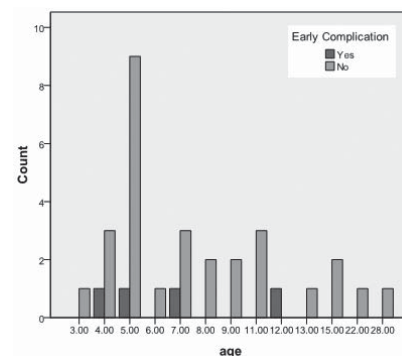


Figure 6: Age versus early complications bar chart

(Fisher’s Exact test) which is not found to be statistically significant. The frequencies of early complications for different type of hypospadias are expressed in table IV.

Late complications: Twelve patients (36.4%) patients developed late complications out of which post-operative urethrocutaneous fistula (Fig: 4) was the most common complication with which was found in 9 patients (27.3%) followed by post-operative meatal abnormality (Fig: 5) which was developed by in 4 patients (12.1%). Figure 8 shows the age distribution of the late complications in the study population. The urethrocutaneous fistula rate was 33% (n=5) in age group < 5 years while 22% (n=4) in age group above 5 years with a p-value of 0.475 with a confidence level of 95% (calculated by chi-Square Test) which is statistically significant (Table: II). The late complication rate (Table: III) was found significantly higher in operation time > 60 minutes group than operation time < 60 minutes with a p-value of 0.133 with a significance level of 95% (Fisher Exact test). The fre-

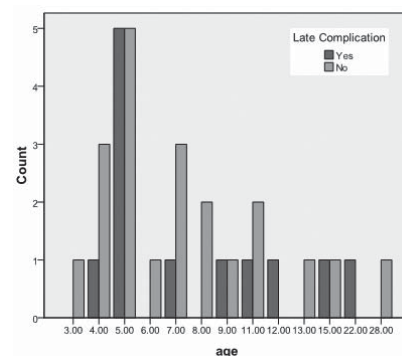


Figure 7: Age versus late complications bar chart

quencies of late complications for different type of hypospadias are expressed in table V.

**Discussion:**

Complications are common after hypospadias repair, ranging from fistulae to complete loss of the neo-urethra requiring total reconstruction<sup>15</sup>. Even in experienced hands, hypospadias repair is associated with the development of urethrocutaneous fistulae. The Snodgrass technique is a simple technical innovation that has revolutionised hypospadias surgery. There are several

Table 1: Operation time versus age group

| Age Group | Operation Time |              | Total      |
|-----------|----------------|--------------|------------|
|           | < 60 minutes   | > 60 minutes |            |
| < 5 Years | 4 (33.3%)      | 8 (66.7%)    | 12 (36.4%) |
| > 5 Years | 11 (52.4%)     | 10 (47.6%)   | 21 (63.6%) |
| Total     | 15 (45.4%)     | 18 (54.54%)  | 33         |

*p*-value = 0.469 with a confidence interval of 95%

Calculated by Fisher's Exact test

*p*-value > 0.5 is significant

Table 2: Urethrocuteaneous fistula versus age group

| Age Group | Post-operative Urethrocuteaneous Fistula |            | Total       |
|-----------|--|------------|-------------|
|           | Yes                                      | No         |             |
| < 5 Years | 5 (33.3%)                                | 10 (66.7%) | 15 (45.45%) |
| > 5 Years | 4 (22.2%)                                | 14 (77.7%) | 18 (54.54%) |
| Total     | 9 (27.3%)                                | 24 (72.7%) | 33          |

*p*-value = 0.475 with a confidence interval of 95%

Calculated by Chi-Square test

*p*-value < 0.5 is significant

Table 3: Operation time versus late complication rate

| Operation Time | Late Post-operative Complications |            | Total      |
|----------------|-----------------------------------|------------|------------|
|                | Yes                               | No         |            |
| < 60 minutes   | 2 (16.7%)                         | 10 (83.3%) | 12 (36.4%) |
| > 60 minutes   | 10 (47.6%)                        | 11 (52.4%) | 21 (63.6%) |
| Total          | 12 (36.4%)                        | 21 (63.6%) | 33         |

*p*-value = 0.133 with a confidence interval of 95%

Calculated by Fisher exact test

*p*-value < 0.5 is significant

Table 4: Type of hypospadias and early complication rate

| Type of Hypospadias | Early Complications |            | Total      |
|---------------------|---------------------|------------|------------|
|                     | Yes                 | No         |            |
| Glanular            | 0 (0%)              | 4 (12.12%) | 4 (12.12%) |
| Coronal             | 0 (0%)              | 8 (24.24%) | 8 (24.24%) |
| Distal Penile       | 3 (9.1%)            | 13 (39.4%) | 16 (48.5%) |
| Mid-Penile          | 1 (3.03%)           | 4 (12.12%) | 5 (15.15%) |
| Total               | 4 (12.12%)          | 29 (87.9%) | 33         |

Table 5: Type of hypospadias and late complication rate

| Type of Hypospadias | Late Complications |             | Total      |
|---------------------|--------------------|-------------|------------|
|                     | Yes                | No          |            |
| Glanular            | 0 (0.00%)          | 4 (12.12%)  | 4 (12.12%) |
| Coronal             | 4 (12.12%)         | 4 (12.12%)  | 8 (24.24%) |
| Distal Penile       | 6 (18.9%)          | 10 (30.30%) | 16 (48.5%) |
| Mid-Penile          | 2 (6.06%)          | 3 (9.09%)   | 5 (15.15%) |
| Total               | 12 (36.4%)         | 21 (63.63%) | 33         |

reasons for this great popularity, including its technical simplicity, and its great versatility and excellent cosmetic results. In 1996, Snodgrass reported the results of treatment of 328 patients with distal hypospadias, in whom an overall complication rate of 7% was found<sup>16</sup>.

In the current study the mean age was 8.33±5.44 years which is comparable with 9.93 ± 4.4 years shown by Tabassi KT et al.<sup>17</sup> in their study from Iran and contrary to 22.72 ± 7.75 months by Al-Saied et al.<sup>18</sup> in their study from Saudi Arabia. The location of the hypospadias in our study (48.5% had distal penile hypospadias while 24.2% had coronal hypospadias) is similar to the results reported by Tabassi KT et al.<sup>17</sup> (distal penile in 59% cases).

The main complication of hypospadias repair in this series is Urethrocuteaneous fistula which is found in 27.3% cases. Dodson JL et al.<sup>19</sup> reported fistula rate of 50% in their study which higher than the current study. Braga LHP et al.<sup>20</sup> reported fistula formation rate of 14% which is lower than our study. Fistula formation has multifactorial etiology i.e. surgical technique, delicate tissue handling, patients' age, type of hypospadias defect, surgeon experience, waterproof urethroplasty coverage, and concomitant foreskin reconstruction<sup>20</sup>. In our study the fistula rate was slightly higher because of the learning curve.

The meatal abnormality was noted in 12.1% cases in this series which comparable with 10.34% reported by Tabassi KT et al.<sup>17</sup>. Other studies have shown frequency of meatal abnormalities (stenosis) from 6-20%<sup>21-28</sup>.

In our study the fistula rate was found significantly lower when performed in age group above 5 years which may be due to the adequate phallus size. The late complications frequencies were found higher when the operation time was higher than 60 min.

This study was conducted on a small population therefore larger studies are suggested to confirm the outcome of Snodgrass repair in the hypospadias repair.

### Conclusion:

The current study conclude that post-operative urethrocutaneous fistula is the main complication of hypospadias repair, its rate is significantly lower in age group above 5 years and the complication frequency increases when the operation time is more than 60 min. Snodgrass repair has acceptable complications rates in the hypospadias repair. Further multi-centre studies are suggested to confirm the results in our setup.

### Reference:

- Aslam M, Obaidullah, Majid A. Two Stage Aivar Bracka repair in Hypospadias salvage cases. *JPMI* 2006;20(2):203-6.
- Gallentine ML, Morey AF, Thompson IM Jr. Hypospadias: a contemporary epidemiologic assessment. *Urology* 2001;57:788-90.
- Bath AS, Bhandari PS, Mukherjee MK, Repair of distal Hypospadias by the tabularized incised plate Urethroplasty: A simple versatile technique. *Indian J Plast Surg* 2003; 36(1):23-5.
- Erol A, Baskin LS, Li YW, Liu WH. Anatomical studies of the urethral plate: why preservation of the urethral plate is important in hypospadias repair: *BJU International* 2000;85(6):728-734.
- Khuri FJ, Hardy BE, Churchill BM. Urologic anomalies associated with hypospadias. *Urol Clin North Am* 1981;8: 565-71.
- Baskin LS, Ebber MB. Hypospadias: anatomy, etiology and technique. *J-Pediatric-Surg* 2006;41(3):463-72.
- G'eraudie J, Ferrettib P. Gene expression during amphibian limb regeneration. *International Review of Cytology* 1998;180:1-50.
- Zhu C.C, Yamada G, Nakamura S, Terashi T, Schweickert A, Blum M. Malformation of trachea and pelvic region in gooseoid mutant mice. *Developmental Dynamics* 1998; 211(4):374-81.
- Stokowski LA. Hypospadias in the neonate. *Adv Neonatal Care* 2004;4:206-15.
- Aslam M, Obaidullah, Mumtaz N. Outcome of Urethra Cutaneous fistula repair after Hypospadias. *Pakistan J. Med. Res* 2005;44(1):23-6.
- Djordjevic ML, Perovic SV, Salvkovic Z, Djakovic N. Longitudinal dorsal dartos flap for prevention of fistula after a Snodgrass Hypospadias procedure. *Eur-Urol* 2006;50(1): 53-7.
- Bracka A. Hypospadias repair: The two-stage alternative. *Br J Urol* 1995;76(3 suppl):31-41.
- Chrzan R, Dik P, Klijin AJ, de-Jong TP. Quality assessment of Hypospadias repair with emphasis on techniques used and experience of pediatric urologic surgeons. *Urology* 2007;70(1):148-52.
- Obaidullah, Aslam M, Ten year review of Hypospadias surgery from a single center. *BJPS* 2005;58(6):780-89.
- Rickwood AM, Anderson PA. One-stage hypospadias repair: experience of 367 cases. *Br J Urol* 1991; 67: 424-28.
- Snodgrass W, Koyle M, Manzoni G, et al: Tubularized incised plate hypospadias repair: results of a multicenter experience. *J Urol* 1996;156:839-41.
- Tabassi KT, Mohammadi S. Tunica Vaginalis Flap as a Second Layer for Tubularized Incised Plate Urethroplasty. *Urol J* 2010;7:254-7.
- Al-Saied G, Gamal A. Versatility of tubularized incised plate urethroplasty in the management of different types of hypospadias: 5-year experience. *Afr J Paediatr Surg* 2009;6:88-92.
- Dodson JL, Baird AD, Baker LA, Docimo SG, Mathews RI. Outcomes of delayed hypospadias repair: implications for decision making. *J Urol.* 2007;178:278-81.
- Braga LHP, Lorenzo AJ, Salle JLP. Tubularized incised plate urethroplasty for distal hypospadias: A literature review. *Indian J Urol* 2008; 24(2): 219-25.
- Moradi M, Moradi A, Ghaderpanah F. Comparison of Snodgrass and Mathieu surgical techniques in anterior distal shaft hypospadias repair. *Urol J.* 2005;2:28-30.
- Al-Hunayan AA, Kehinde EO, Elsalam MA, Al-Mukhter RS. Tubularized incised plate urethroplasty: Modification and outcome. *Int Urol Nephrol.* 2003;35:47-52.
- Soygur T, Arikan N, Zumrutbas AE, Gulpinar O. Snodgrass hypospadias repair with ventral based dartos flap in combination with mucosal collars. *Eur Urol.* 2005;47:879-84.
- Mustafa M. The concept of tubularized incised plate hypospadias repair for different types of hypospadias. *Int Urol Nephrol.* 2005;37:89-91.
- Bar-Yosef Y, Binyamini J, Mullerad M, Matzkin H, Ben-Chaim J. Megameatus intact prepuce hypospadias variant: Application of tubularized incised plate urethroplasty. *Urology.* 2005;66:861-4.
- Tonvichien L, Niramis R. Tubularized, incised plate urethroplasty in hypospadias repair: Experience at Queen Sirikit National Institute of Child Health. *J Med Assoc Thailand.* 2003;86:S522-30.
- Stehr M, Lehner M, Schuster T, Heinrich M, Dietz HG. Tubularized incised plate (TIP) urethroplasty (Snodgrass) in primary hypospadias repair. *Eur J Pediatr Surg.* 2005;15:420-4.
- Leclair MD, Camby C, Battisti S, Renaud G, Plattner V, Heloury Y. Unstented tubularized incised plate urethroplasty combined with foreskin reconstruction for distal hypospadias. *Eur Urol.* 2004;46:526-30.