

Diagnostic dilemma of Intracranial fungal granuloma risk versus benefit assessment before Neurosurgical management

Saeed Mazher, Abdul Ali Khan, Zaheen Shibli, Abdul lateef, Shafaatullah, Zeeshan Faisal

Abstract

Objective: MRI and outcome based learning experience in the management of intracranial fungal granulomas and atypical brain infections (IFG) considering risk versus benefit before neurosurgical interventions.

Material and Methods: We performed a retrospective analysis of all patients with diagnosed IFG or anticipated diagnosis based predominantly on imaging from 2011 to 2019 collected data included clinical history, lab results treatment and review of all imaging studies performed. Among these cases, one case required additional consideration of histo-pathological confirmation due to refractory response to anti-fungal medication and subsequent deterioration of neurology of patient hence neurosurgical intervention was done in that individual case. The organized data covered clinical history, lab results and treatment outcome, review of imaging.

Results: The most prominent symptoms noted were headache 80%, proptosis 20%, hypertelorism and visual diminution. Other symptoms like unilateral body weakness and cranial neuropathies were found among couple of patients. Pre-disposing risk factors notified were diabetes, renal dialysis and preexisting tumor. Location was primarily frontal 1 parasellar 1 in each involvement. One patient underwent frontal craniotomy for resection of fungal granuloma abscess histopathology revealed aspergilloma. All patients were treated with itraconazole except the one in whom the isolated bacterial organism was reported therefore she was kept on sensitive antibiotics for 3 to 6 months. Few were offered fluconazole, flucytosine and amphotericin B for a brief period. Mortality 1 secondary to meningo-encephalitis.

Conclusion: Early diagnosis, risk versus benefit assessment oriented surgical decompression and prophylactic anti-fungal course according to variability of case with prompt initiation of antifungal therapy showed better outcome. Administration of itraconazole therapy showed improvement in the clinical neurology and over all outcomes with in the period of 6 months to one year. In future perspective, firm clinical therapeutic recommendations can be established by the help of larger trials

Keywords: Intracranial fungal granuloma (IFG), Antifungal therapy (AFT), Rhino-orbital cerebral mucormycosis (ROCM)

Introduction:

Fungal infection of the central nervous system are rare clinical entities presenting with protean clinical manifestation difficult diagnostic dilemma and special therapeutic challenge.^{2,3}

Rhino-orbital-cerebral mucormycosis (ROCM) is an uncommon acute and aggressive fungal in-

fection occurring in several immuno-compromised states including diabetes, which is the most common (60%-80%) predisposing factor.^{4,5}

The disease originates in the nasal, sinus mucosa after inhalation of fungal spores and takes a rapidly progressive course extending to neighbor-

Received

Date: 4th January 2020

Accepted

Date: 22nd September 2020

Baqai University
Hospital, Karachi

S Mazher
AA Khan
Z Shibli
A Lateef
Shafaatullah

Hamdard University
Hospital, Karachi

Z Faisal

Correspondence:

Dr Saeed Mazher
Assistant Professor
Neurosurgery Department
Baqai University Hospital
Karachi
Cell No:+92 300-9291975
email: dribnemaryem@
gmail.com

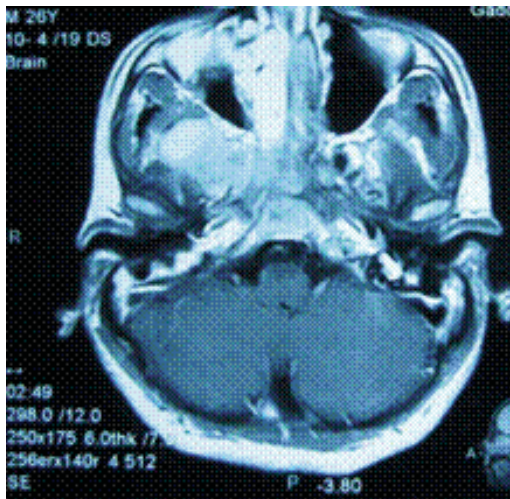


Figure 1: Pre treatment imaging filling ethmoid and sphenoid sinuses

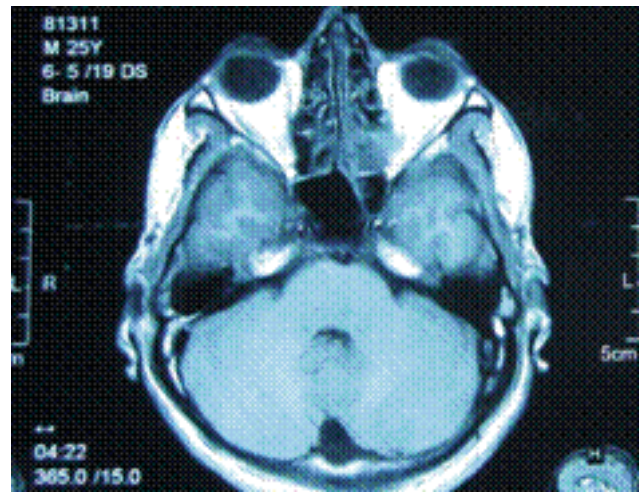


Figure 2: Post treatment imaging showing clear ethmoid and sphenoid sinuses

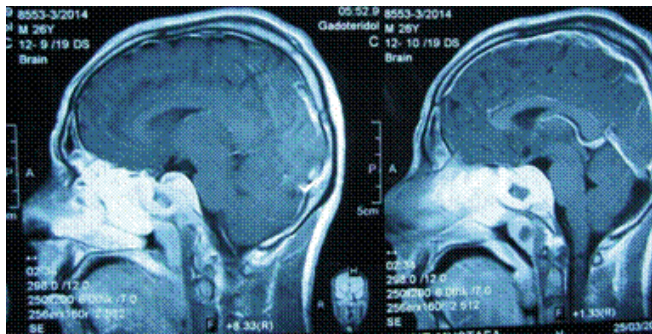


Figure 3: Pre treatment of same patient with involved all sinuses extending up to clivus and brain stem.

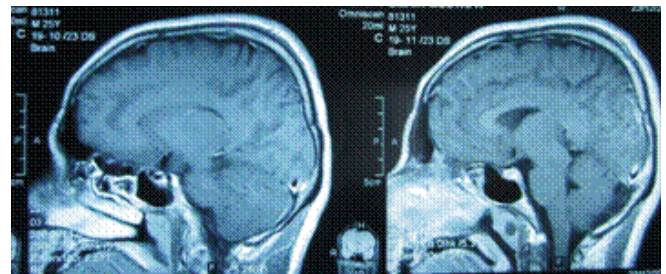


Figure 4: Post treatment of same patient clearance of pathology from all involved areas.

ing tissue, including the orbit and sometimes brain. Gregory et al in 1943 reported three cases of ROCM in patients with uncontrolled diabetes with unilateral orbital cellulitis, complete ophthalmoplegia, cerebral invasion and death.⁶ ROCM causes very high residual morbidity and mortality due to the angio-invasive property of the fungus, thereby causing vascular occlusion and consequently resulting in extensive tissue necrosis.⁷ Impaired delivery of the anti-fungal drug to the site of infection because of vascular thrombosis and limited aggressive surgery because of complex anatomy of rhino-orbital region cautions for early diagnosis and aggressive management of these patients.

We present the complete profile and treatment

outcome of sporadically 10-fungal cases and a typical bacterial case in our tertiary care teaching centers. The objective of this article is to develop a consensus about the management of intra-cranial fungal disease which requires thorough clinical assessment, specific laboratory, follow up imaging and medicine monitoring. Although diagnostic expertises are available, regarding early confirmation of disease with prompt identification of risk factors. It requires contributions from infectious and otolaryngology department. Due to the aggressive nature of the disease the duration of anti fungal therapy should also be rationalized in the light of study and literature review.

In case-1 who is a 9 yrs old male patient was

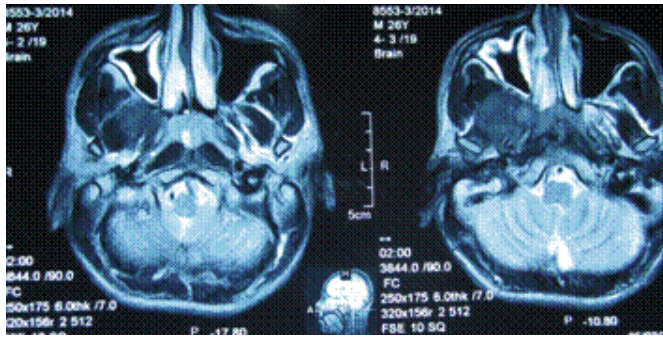


Figure 5: Pre treatment involved maxillary sinus

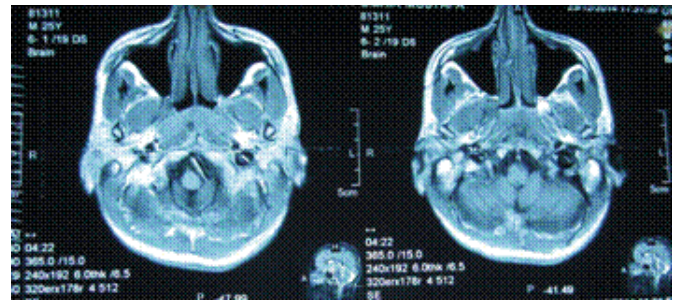


Figure 6: Post treatment clear maxillary sinus

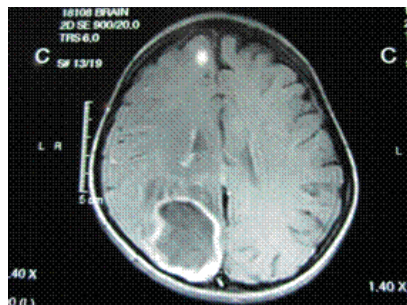


Figure 7: Pre intervention occipital uneven rim enhanced lesion

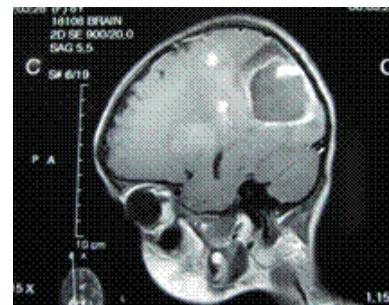

Figure 8: Pre intervention occipital uneven rim enhanced lesion

on dialysis presented with complain of headache fever and visual deterioration. During his stay in the hospital he had undergone complete workup in terms blood biochemistry septic profile and Magnetic resonance imaging which revealed as frontal lobe lesion. Frontal craniotomy and excision of frontal mass was done and biopsy showed fungal lesion and isolation of aspergillus. Hence patient was kept on antifungal medications after consultation by infectious disease department and continued for about five years in two phases. In the Initial phase amphotericin B was given in the ICU setting and after couple of weeks therapy due to emerging toxic effects of drug patient was kept on itraconazol for a about five year in close follow up. Later on he developed hydrocephalus and was treated by performing diversion procedure.

In case-2 who is a 26 years old male patient presented with complain of head ache, proptosis right eye and diminution of vision. Magnetic

resonance imaging revealed parasellar mass extending in the orbit with the invasion of paranasal sinuses. He was kept on itraconazol for a period of 9-months with in a phase of two to three months he responded well in terms of resolution of proptosis and improvement in symptoms. He stopped taking anti fungal medications and lost to follow up. Then he re-appeared with limping gate after a period of 4 to 5 months secondary to persistent signs and symptoms subsequent to discontinuation of anti-fungal treatment. Repeat scanning revealed expansion of lesion and involvement of brain stem hence the patient was again kept on anti-fungal treatment (itraconazol) with more vigilance and close follow ups. Patient responded well in terms of improvement of gait within the period of 6 months to one year as shown in figure-6.

In case-3 who is a 8 years old girl presented with complaint of fever, headache and fits. On enquiry there was a history of fall from stairs.

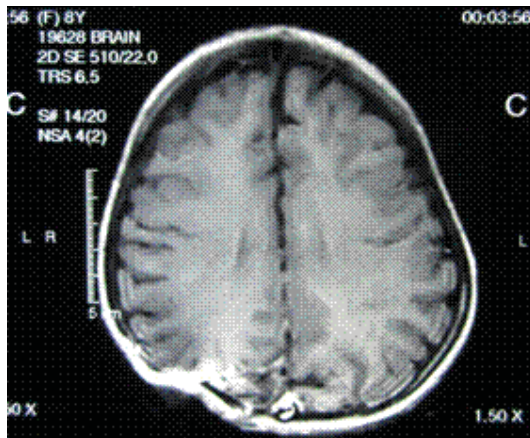


Figure 9: Post intervention excision of lesion with resolution of lesion

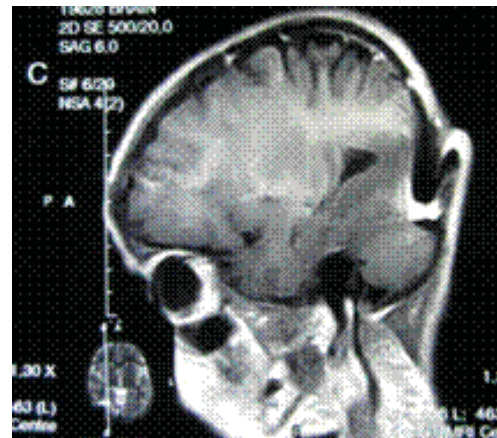


Figure 10: Post intervention excision of lesion with resolution of lesion

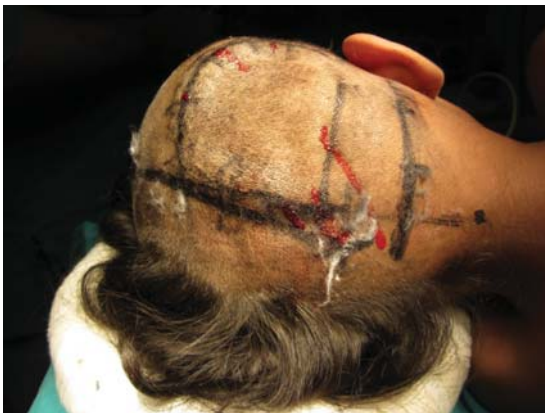

Figure 11:

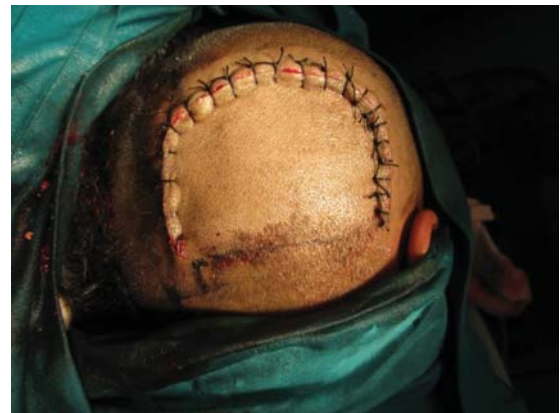

Figure 12:

MRI brain revealed right occipital un-even rim enhance lesion. After optimization of patient, informed consent was obtained.

There after the lesion was accessed by proper right occipital broad based craniotomy, frank yellow colored pus was drained after localization of lesion by the help of brain needle and the debris cavity was identified and washed with antibiotic mixed saline multiple times. After homeostasis closure was performed. Pus was sent for gram staining, AFB culture and fungal smears. Tissue was also sent for histo-pathology. Results revealed bacteria growth and sensitive antibiotics hence patient was kept on antibiotics accordingly for a period of more than 3 months with uneventful recovery. The patient remains in close follow up for more 3-years without any recurrence.

Discussion:

In the view of these findings, we reviewed the clinical courses of ten assessable patients based on MRI and CT scan clearance along with clinical improvement, unchanged and worsening status. All these patients were kept on itraconazol due to tentative diagnosis based on MRI findings like involvement of nasal, para-nasal sinuses, intra-cranial extension or rhino-orbital penetration. In one of ten patients the combination of amphotericin-B and itraconazol was given pre-operatively by the consultation of infectious disease department. The prompt neuro-surgical intervention results in eradication of intra-cranial fungal abscess with isolation of Aspergillus and subsequent development of hydrocephalus which was dealt by the help diversion procedure. That vary patient was kept on antifungal therapy for prolong period.

In 3 of 10 patients single itraconazol therapy along with close follow up and monitoring successfully eradicated the mycosis with improvement of clinical symptom. Although one patient developed relapse due to abrupt discontinuation of anti-fungal therapy (itraconazol) after resolution of symptoms, hence he was offered a combination therapy of flucytosine and itraconazol. He had also attained complete recovery. Before prescribing flucytosine the whole work-up for immuno-compromised status was done including cbc, septic profile (ESR CRP), LFT and HIV screening. On enquiry that patient was taking steroids for the purpose of body building. Remaining patients were kept on single itraconazol therapy and they responded well. Except two patients who could not survive due to sudden deterioration despite continuing anti-fungal treatment secondary to other factors like cancer. In the literature review it is well documented due to severe adverse effects of different anti-fungal medications it is always necessary to monitor drug levels.⁸⁻¹¹ if needed, more over Alt, Ast, Alkaline phosphatase, anemia, granulocytopenia and thrombocytopenia should also be considered while continuing flucytosine therapy.^{12,13}

Due to the aforementioned monitoring adverse effects and multiple risk involvement we had to discontinue flucytosine. Moreover the availability of flucytosine was also become difficult for single patient of our series.

In this study, there was a limited usage of flucytosine as it was offered to only single patient due to relapse of disease and immuno-compromised status confirmation. Hence some larger studies will be more appropriate in deciding the cause and effect of application of this combination antifungal therapy.

In the literature review it is well documented that intra-cranial fungal masses can be seen at any age but most patients are in the third, fourth and fifth decades of life. There are reported cases in neonates, infants and young children.¹⁴ The duration of symptoms can vary from days to several months or even years.¹⁵⁻¹⁷

The clinical presentation can be categorized in to three groups.

1. Involvement of cranial nerves 1 to 6
2. Focal neurological deficit
3. Stroke like presentation with sudden onset of hemiparesis.

There are other possibilities like altered sensorium and seizures. Rarely, patients with fungal aneurysm present with subarachnoid hemorrhage. Fever has also been observed with Intracranial fungal masses but in only 10 – 31% of patients.¹⁸

Based on the presence or absence of radiological evidence of CNS disease. IFM were in to two types

1. Rhino cerebral type
2. Pure intracranial type further divided in to intra cerebral or extra cerebral form.

More over some of the patients with intra fungal masses also presented with fever ranging 10-31% of patients. While in over series we could find out such clinical picture among few cases.

The largest case series reported to date has 40 patients gathered over 22-years from four centers one in India and the other in the United States.¹⁵

Even in the aforementioned research article it is demonstrated that due to the reason of immuno-compromised issues fungal infection rate is increasing as compared to previous era. Moreover it is also well documented that despite having large series of patients in a long span period of time, management of intra-cranial fungal granuloma has not been standardized. Although anti-fungal medication is the primary treatment but the role of surgery in terms of minimally invasive biopsy, craniotomy (open excision biopsy), FESS (fibro-optic endoscopic sinus surgery) and ventriculo peritoneal shunt placement is mandatory in selected cases and produces rewarding outcome. The duration of anti-fungal

anti-biotic therapy has not been clearly elucidated in the literature. This article will be helpful in reviewing the prognostic factor and outcome based role of surgery reported in literature. It may give an idea as to how long the anti-fungal treatment should be continued if the literature review highlights this aspect of the challenging rare disease.

In our study we had continued anti-fungal therapy for about 1 to 5 years depending on the clinical response and radiological images resolution of the disease, more over some large clinical trials would be more beneficial in addressing about duration of therapy.

High mortality and morbidity have been uniformly reported in almost all series of patients with intra-cranial fungal granuloma. The mortality rate of 63 percent was reported by Dubey et al¹⁵ in their series of 40-patients with intracranial fungal masses. Two third of patients had predisposing illness (diabetes, tuberculosis, renal transplant & dialysis). Mortality in immunocompetent patients with intra cerebral aspergillosis was 66.7% in the series reported by Siddiqui et al,¹⁷ while in our series of 10-patients we found 20% mortality.

Similarly in our small case series of 10 patients over the time span of approximately 9-years. We found that one was reported Rhino cerebral type with frontal lobe involvement and Aspergillus species was the causative agent. Who required abscess drainage by proper craniotomy and subsequent ventriculo-peritoneal shunt placement due to post craniotomy development of hydrocephalus. Afterwards the patient was kept on prolong anti-fungal therapy along with short duration initial phase of combination amphotericin-B anti-fungal therapy in intensive care unit setting. While in rest of cases, temporal lobe, frontal lobe, seller and para seller areas were found to be involved on imaging

Conflict of interest: None

Funding source: None

Role and contribution of authors:

Dr. Saeed Mazher, collected the data, references and did the initial writeup

Dr. Abdul Ali Khan, collected the data and helped in introduction writing

Dr. Zaheen Shibli, collected the references and helped in discussion writing.

Dr. Abdul lateef, collected he data and helped in interpretation of data.

Dr. Shafaatullah, collected the data, references and helped in compiling the result.

Dr. Zeeshan Faisal, critically review the article and made final changes.

References:

1. Vedanta Rajshekhar. Surgical management of intracranial fungal masses: review article. 2007;55:3:267273.
2. Asic EJ, Meginnie MR, Pfaller MA, editors clinical mycology new York churchill living stone; 2003.
3. Sharma RR, Lad SD, Pawar SJ, Gurusinghe NT, bhagwati SN, Mahapatra AK. Surgical management of fungal infections of the central nervous system. In :Schmedek HH, Roberts DW,editors. Schmedek & sweets operative neurosurgical techniques, indications, methods and results. 5th ed ; 2006.p.1633-71.
4. Yohai RA, Bullock JD, Aziz AA, et al. Survival factors in rhino-orbital-cerebral mucormycosis: major review. Surv Ophthalmol 1994; 39: 3-22.
5. Ferry AP, Abedi S. Diagnosis and management of rhino-orbitocerebral mucormycosis (phycomycosis): a report of 16 personally observed cases. Ophthalmology 1983;90:1096-104
6. Gregory JL, Golden A, Haymaher W. Mucormycosis of the central nervous system: a report of three cases. Bull John Hopkins Hosp 1943;73:302-13
7. Parfrey NA. Improved diagnosis and prognosis of mucormycosis: a clinicopathologic study of 33 cases. Medicine 196;65:113-23
8. Utz JP, garriques IL, sande MA, et al. Therapy of cryptococcosis with a combination of flucytosine and amphotericin B. J Infect Dis 1975;132:368-73.
9. Bennett JE, Dismukes WE, Duma RJ, et al. A comparison of amphotericin B alone and combined with flucytosine in the treatment of cryptococcal meningitis. N Engl J Med 1979;301:126-31.
10. Eilard T, alesting K, wehlen P. treatment of disseminated candidiasis with 5-fluorocytosine. J infect Dis 1974;130:159-9.
11. Physicians' Desk Reference. Oradell, NJ: Medical economics, 1992:1886.
12. Dismukes WE, Cloud G, Gallis HA, et al. national Institute of Allergy and infectious Diseases Mycoses study group. Treatment of cryptococcal meningitis with combination amphotericin B plus flucytosine for four as compared with six weeks. N Engl J med 1987; 17 : 334-41.
13. Stamm AM, Diasio RB, Dismukes WE, et al. Toxicity of amphotericin B plus flucytosine in 194 patients with cryptococcal meningitis. Am J Med 1987;83:236-42.
14. Marcinkowski M, Bauer K, Stoltenburg-Didinger G, et al. Fun-

- gal brain abscess in neonates: Sonographic appearances and corresponding histopathologic findings. *J Clin Ultrasound* 2001;29:417-21 [PUBMED]
15. Dubey A, Patwardhan RV, Sampath S, et al. Intracranial fungal granuloma: Analysis of 40 patients and review of the literature. *Surg Neurol* 2005;63:254-60
16. Nadkarni T, Goel A. Aspergilloma of the brain: An overview. *J Postgrad Med* 2005;51:37-41
17. Siddiqui AA, Shah AA, Bashir SH. Craniocerebral aspergillosis of sinonasal origin in immunocompetent patients: Clinical spectrum and outcome in 25 cases. *Neurosurgery* 2004;55:602-13 [PUBMED]
18. Hurst RW, Judkins A, Bolger W, et al. Mycotic aneurysm and cerebral infarction resulting from fungal sinusitis: Imaging and pathological correlation. *AJNR Am J Neuroradiol* 2001;22:858-63